



Case report

Dyspareunia caused by a vaginal adhesion band following a transvaginal mesh repair

Cheng-Yu Long^{a,b}, Ming-Ping Wu^{c,d,e,*}^a Graduate Institute of Medicine, Center of Excellence for Environmental Medicine, Kaohsiung Medical University, Kaohsiung, Taiwan^b Department of Obstetrics and Gynecology, Kaohsiung Municipal Hsiao-Kang Hospital, Kaohsiung Medical University, Kaohsiung, Taiwan^c Division of Urogynecology and Pelvic Floor Reconstruction, Department of Obstetrics and Gynecology, Chi Mei Foundation Hospital, Tainan, Taiwan^d College of Medicine, Taipei Medical University, Taipei, Taiwan^e Center of General Education, Chia Nan University of Pharmacy and Science, Tainan, Taiwan

ARTICLE INFO

Article history:

Received 16 May 2012

Received in revised form

9 April 2013

Accepted 10 May 2013

Available online 28 June 2013

Keywords:

Dyspareunia

Pelvic organ prolapse

Prolift

Vaginal adhesion band

ABSTRACT

Surgery with synthetic mesh or graft materials has become increasingly popular over the past decade due to the excellent short-term success rate. However, concern about mesh-related complications still exists. Here we report a case experiencing sexual pain after a transvaginal mesh repair with a total Prolift procedure. Also, her husband experienced painful intercourse due to a vertical adhesion band between the anterior and posterior vaginal wall. Under local anesthesia, the adhesion band was dissected. She restarted her sexual life 3 weeks after the procedure without any further complaint. A postoperative vaginal adhesion band formation may occur during the healing process, which may cause postoperative sexual dysfunction. This rare complication may aid in preoperative counseling about the potential adverse events on postoperative sexual function.

Copyright © 2013, The Asia-Pacific Association for Gynecologic Endoscopy and Minimally Invasive Therapy. Published by Elsevier Taiwan LLC. All rights reserved.

Introduction

Approximately 11.1% of women are at risk of receiving any type of operation for pelvic organ prolapse (POP) or urinary incontinence in their lifetime, with up to 29% of a repeated operation for recurrence within 5 years.¹ Traditionally, anterior and posterior colporrhaphy with vaginal hysterectomy has been used to treat POP in the past, with an unacceptable recurrence rate.^{1,2} Therefore, a transvaginal repair with an inlay synthetic mesh or graft materials has become increasingly popular over the past decade due to the excellent short-term success rate.^{3,4} However, concern about mesh-related complications still exists following these transvaginal mesh (TVM) surgeries.

Prolift systems (Gynecare Prolift; Ethicon, Inc., Bridgewater, NJ, USA) is one of the most popular mesh kits recently developed and adopted in pelvic reconstructive surgery. It is used to reinforce the pubocervical and/or rectovaginal fascia and to provide a strong pelvic floor support. As life expectancy increases, changes in sexual function following TVM repair have become a critical issue that needs to be discussed with patients in addition to anatomical

restoration when providing consultation about pelvic reconstructive surgery.

A "condom-like" effect proposed by Su et al⁵ was found in women with total TVM repair encircling the entire vagina, which may have the adverse effect on sexual function at 6 months after surgery. We have also found that women undergoing TVM repair may experience sexual impairment.⁶ However, TVM-induced vaginal adhesion has never been reported. Here we report a case experiencing sexual pain induced by vaginal vertical adhesion after a total Prolift procedure.

Case report

A 56-year-old multiparous woman came to our gynecological clinic with a nontender protruding mass, noted for about a year. The vaginal mass bulged intermittently, especially when coughing, squatting, or having bowel movements. Occasionally, she had urinary urgency and hesitancy in voiding in a full bladder. Pelvic examination revealed Stage 4 total prolapse of the anterior, posterior, and apical compartments. The urodynamic finding was an obstructive voiding pattern with normal storage function.

After giving informed consent, she received a TVM with a total Prolift procedure. All procedures were performed as previously reported.⁴ During anterior mesh repair, superior trocars of both

* Corresponding author. Division of Urogynecology and Pelvic Floor Reconstruction, Department of Obstetrics and Gynecology, Chi Mei Foundation Hospital, Number 901, Chung Hwa Road, Yung Kang, Tainan, Taiwan.

E-mail address: mpwu@mail.chimei.org.tw (M.-P. Wu).

devices were inserted through the upper medial angle of the obturator foramen at the level of the clitoris, while the inferior trocars were inserted 2 cm inferior and 1 cm lateral to the upper incisions. All trocars are designed to pass through the "arcus tendineus" and emerge with the vaginal incision.

In the Prolift procedure for apical and posterior prolapse, the trocar was inserted 3 cm lateral and inferior to the anus. The needle is designed to pass through the sacrospinous ligament at a level of 2 cm posterior and medial to the ischial spine. Then, cystoscopy was performed to exclude any bladder injury and to confirm intact ureters. The synthetic mesh was positioned under the bladder and fixed with 3-0 Prolene sutures proximally and distally. The vaginal mucosa is closed with 3-0 polyglactin sutures. The skin incisions are closed using Dermabond and vaginal packing was placed for 24–48 hours. The patient was given antibiotic prophylaxis (intravenous Cefazolin 1 g; Cefamezin, Fujisawa, Tokyo, Japan) administered prior to surgery.

Follow-up was scheduled at postoperative first and fifth weeks. No local adhesion, hematoma, or infectious sign were found. All anatomical points of the POP-Q system showed excellent restoration. She applied topical estrogen 1 g (0.625 mg conjugated equine estrogen per 1 g vaginal cream: Premarin vaginal cream; Ayerst, Inc., New York, NY, USA) twice a week. She started to have sexual activity 2 months after surgery. Unfortunately, she felt intractable pain during penile penetration. Her husband also experienced painful intercourse.

Pelvic examination revealed a vertical adhesion band over the upper half of the vagina, between the anterior and posterior vaginal wall (Fig. 1). No mesh extrusion was found. Under local anesthesia, the vertical vaginal band was pulled out by a grasper (Fig. 2), and separated by Metzenbaum scissors. No suture was done due to the absence of active bleeding during the procedure. Postexcisional recovery was uneventful. She restarted her sexual life 3 weeks after the procedure without any further complaint.

Discussion

In an attempt to improve the outcome of traditional transvaginal repair, the use of synthetic materials has been increasingly adopted to augment POP repair despite insufficient evidence concerning long-term safety. The impact of TVM repair on female sexual function is well documented.⁵ Dyspareunia and penile injury are a unique complication associated with TVM surgery.

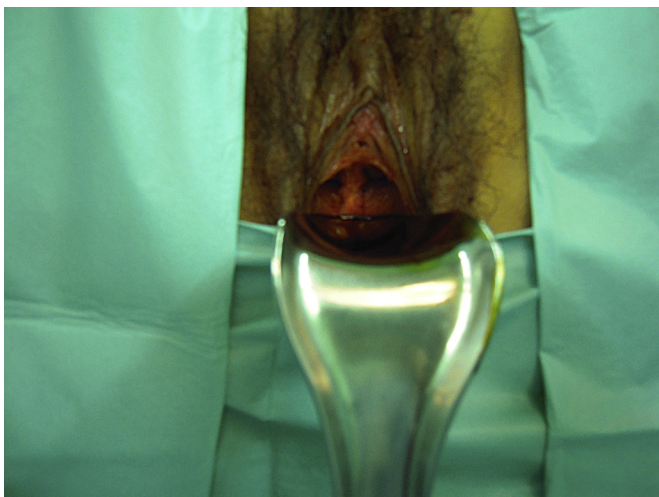


Fig. 1. On pelvic examination, a vertical adhesion band is seen between the anterior and posterior vaginal wall.

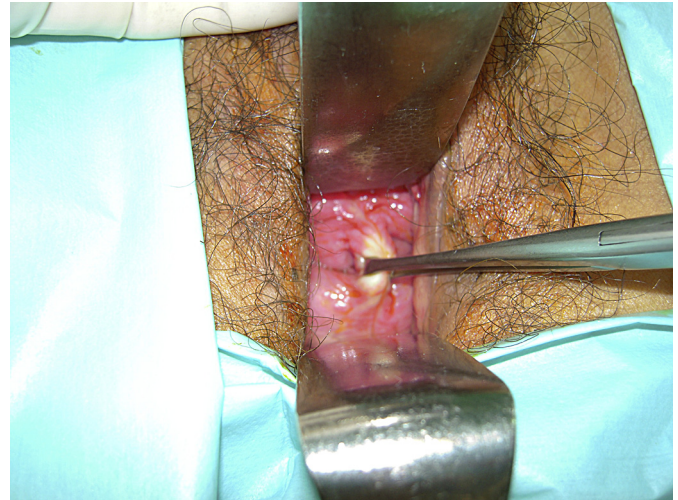

Fig. 2. The vertical vaginal band can be pulled out easily by a grasper.

Dyspareunia has been one of the concerns associated with the use of synthetic meshes, ranging from 20% to 36% in previous studies.⁷

Any vaginal mesh surgery involving the anterior vaginal wall may cause the formation of vaginal fibrosis. These may result in painful intercourse, as well as consequent arousal and orgasmic disorders.⁸ A previous study reported a lower female sexual function index score among dyspareunia, desire, and lubrication domains following TVM repair, although a remission was observed with a time lapse at 6 months follow-up.⁹ However, painful intercourse was unlikely to be relieved with time in our patient, unless her vaginal adhesion band was removed.

A condom-like effect was proposed to explain the phenomenon that total TVM repair encircled the entire vagina, which had an adverse effect on sexual function postoperatively.⁵ Our recent study also found that women undergoing total (i.e., both anterior and posterior) TVM experienced a greater sexual impairment than those women who had anterior mesh surgery alone.¹⁰ In addition, a vaginal adhesion band may occur because the anterior and posterior vaginal wounds contact together during the healing process. This further resulted in postoperative sexual dysfunction. The condition is not specific to TVM as the wound of the anterior and posterior colporrhaphy are also in close proximity, which may induce adhesion during healing.

The TVM procedure creates an effective anatomical restoration of POP, with worsened individual domains of the female sexual function index due to various reasons.^{8–10} This rare complication may aid in preoperative counseling about the potential adverse events on postoperative sexual function. Nevertheless, more case accumulations are warranted to confirm our findings.

Acknowledgments

This study was supported by the Department of Research Education and Training, Kaohsiung Medical University, Kaohsiung, Taiwan.

References

- Olsen AL, Smith VJ, Bergstrom JO, Colling JC, Clark AL. Epidemiology of surgically managed pelvic organ prolapse and urinary incontinence. *Obstet Gynecol.* 1997;89:501–506.
- Hiltunen R, Nieminen K, Takala T, et al. Low-weight polypropylene mesh for anterior vaginal wall prolapse: a randomized controlled trial. *Obstet Gynecol.* 2007;110:455–462.
- Altman D, Väyrynen T, Engh ME, Axelsen S, Falconer C. Anterior colporrhaphy versus transvaginal mesh for pelvic-organ prolapse. *N Engl J Med.* 2011;364:1826–1836.

4. Long CY, Hsu CS, Jang MY, Liu CM, Chiang PH, Tsai EM. Comparison of clinical outcome and urodynamic findings using "Perigee and/or Apogee" versus "Prolift anterior and/or posterior" system devices for the treatment of pelvic organ prolapse. *Int Urogynecol J*. 2010;22:233–239.
5. Su TH, Lau HH, Huang WC, et al. Short term impact on female sexual function of pelvic floor reconstruction with the prolift procedure. *J Sex Med*. 2009;6:3201–3207.
6. Long CY, Hsu CS, Wu MP, Lo TS, Liu CM, Tsai EM. Comparison of the changes in sexual function of premenopausal and postmenopausal women following transvaginal mesh surgery. *J Sex Med*. 2011;8:2009–2016.
7. Deffieux X, de Tayrac R, Huel C, et al. Vaginal mesh erosion after transvaginal repair of cystocele using Gynemesh or Gynemesh-Soft in 138 women: a comparative study. *Int Urogynecol J Pelvic Floor Dysfunct*. 2007;18:73–79.
8. Lakeman MM, van der Vaart CH, Laan E, Roovers JP. The effect of prolapse surgery on vaginal sensibility. *J Sex Med*. 2011;8:1239–1245.
9. Hoda MR, Wagner S, Greco F, Heynemann H, Fornara P. Prospective follow-up of female sexual function after vaginal surgery for pelvic organ prolapse using transobturator mesh implants. *J Sex Med*. 2011;8:914–922.
10. Long CY, Juan YS, Wu MP, et al. Changes in female sexual function following anterior with and without posterior vaginal mesh surgery for the treatment of pelvic organ prolapse. *J Sex Med*. 2012;9:2167–2174.