



## Review article

## Principles of safe abdominal entry in laparoscopic gynecologic surgery



Jongrak Thepsuwan<sup>a</sup>, Kuan-Gen Huang<sup>b,\*</sup>, Muliati Wilamarta<sup>c</sup>, Aizura-Syafnaz Adlan<sup>d</sup>,  
Vahan Manvelyan<sup>e</sup>, Chyi-Long Lee<sup>b</sup>

<sup>a</sup> Department of Obstetrics and Gynecology, Bangkok Hospital Medical Center, Bangkok, Thailand

<sup>b</sup> Department of Obstetrics and Gynecology, Chang Gung Memorial Hospital at Linkou and Chang Gung University College of Medicine, Kwei-Shan, Tao-Yuan, Taiwan

<sup>c</sup> Department of Obstetrics and Gynaecology, Limijati Maternity and Child Hospital, Bandung, Indonesia

<sup>d</sup> Department of Obstetrics and Gynaecology, University Malaya Medical Centre, Faculty of Medicine, University of Malaya, Kuala Lumpur, Malaysia

<sup>e</sup> Department of Operative Gynecology, Shengavit Medical Center, Yerevan, Armenia

## ARTICLE INFO

## Article history:

Received 4 November 2012

Received in revised form

31 May 2013

Accepted 4 June 2013

Available online 30 August 2013

## Keywords:

Complication

Laparoscopy

Lee-Huang point

Palmer's point

Surgery

## ABSTRACT

Laparoscopic gynecologic surgery has been widely used with a range of benefits. However, there are complications that are related to the abdominal entry process. Serious complications are gastrointestinal tract and major blood vessel injuries. This review introduces the recent available literature to prevent and eliminate the laparoscopic entry complications. The open entry technique is associated with a significant reduction of failed entry, compared to the closed entry technique; however there is no difference in the incidence of visceral or vascular injury. Laparoscopic entry by the left upper abdomen (i.e., Palmer's point) or the middle upper abdomen (i.e., the Lee-Huang point) could be considered in patients with suspected periumbilical adhesions or a history of umbilical hernia, or after three failed attempts of insufflation at the umbilicus. The Lee-Huang point has its own benefit for the operative laparoscopy in large pelvic pathologies and gynecology malignancy cases. The angle of Veress needle insertion varies from 45° in nonobese women to 90° in extraordinarily obese women. The high intra-peritoneal pressure entries, which range from 20 mmHg to 25 mmHg, minimize the risk of vascular injury. Therefore, this will not adversely affect the cardiopulmonary function in healthy women. The Veress intraperitoneal pressure (<10 mmHg) is a reliable indicator of correct intraperitoneal placement of the Veress needle. The elevation of anterior abdominal wall for placement of a Veress needle increases the risks of failed entry and shows no advantage in regard to vascular or visceral complications. Surgeons should continue to increase their knowledge of anatomy, their training, and their experience to decrease laparoscopic complications.

Copyright © 2013, The Asia-Pacific Association for Gynecologic Endoscopy and Minimally Invasive Therapy. Published by Elsevier Taiwan LLC. All rights reserved.

## Introduction

Laparoscopy has gradually become popular in gynecology practices because of its many benefits. A meta-analysis of 27 randomized controlled trials (RCTs) that compared laparoscopy and laparotomy for benign gynecological procedures, concluded that there is a 40% lower risk of minor complications after laparoscopic gynecology surgery than after laparotomy; however, the risks of major complications are similar.<sup>1</sup> Compared to laparotomy, laparoscopic surgery for benign ovarian tumors is associated with

reduced surgical complications such as pain and hospitalization, according to the 2005 Cochrane review.<sup>2</sup> There was no difference between the procedures in regard to postoperative infections and tumor recurrence.<sup>2</sup> However, the abdominal entry is a challenging procedure in laparoscopy because of serious complications such as gastrointestinal tract and major blood vessel injuries that account for 50% prior to the commencement of the intended surgery.<sup>3,4</sup> Most injuries are caused by the insertion of the primary trocar.<sup>5</sup> Increased morbidity and mortality occurs if neither the surgeon nor the patient acknowledge the injuries and treat them earlier.<sup>5</sup>

The overall incidence of major injuries at the time of entry is 1.1/1000. Bowel injuries have occurred in 0.7/1000 laparoscopies and major vascular injuries in 0.4/1000 laparoscopies.<sup>6</sup> The incidence of bowel and major vessel injuries are low, but both of these types of injuries are potentially life-threatening, especially during the initial

\* Corresponding author. Department of Obstetrics and Gynecology, Chang Gung Memorial Hospital, Linkou Medical Center and Chang Gung University College of Medicine 5, Fu-Hsin Street, Kwei-Shan, Tao-Yuan 333, Taiwan.

E-mail address: [kghuang@ms57.hinet.net](mailto:kghuang@ms57.hinet.net) (K.-G. Huang).

access. This article will review the principles of safe abdominal entry in laparoscopic surgery to minimize laparoscopic entry complications, based on the best available evidence.

### Entry techniques

#### *The open (Hasson) technique*

The open technique (also called the Hasson technique) is a method in which an incision is made through the abdominal wall under direct vision. The proposed advantages for the open technique are avoidance of blind puncture with a Veress needle, following trocar insertion; establishing a pneumoperitoneum; and correct anatomical repair of the abdominal wall incision. This technique has also been used for lower abdominal surgery, pregnant patients, and very thin women and children who have little space between the abdominal wall and the spine. Reasons for limiting the usage were obese patients, longer time consumption, difficult technique, and pneumoperitoneum maintenance.<sup>7</sup>

#### *The closed (Veress needle) technique*

The closed technique (also called the Veress needle technique) refers to a closed method in which the Veress needle punctures through the layers of the abdominal wall. When the needle enters the cavity, the clinician usually feels or hears the protective sheath clicking when it recoils, indicating that the cavity has been entered. The most common insertion site for the Veress needle is the umbilicus because there is no fat or muscle between the skin and peritoneum. A transumbilical insertion is contraindicated for patients with umbilical abnormalities such as herniation or underlying adhesion.<sup>8</sup>

The Cochrane database of systematic reviews 2012 concluded that the open entry technique is associated with a significant reduction of failed entry (compared to the closed entry technique) with no difference in the incidence of visceral or vascular injury; the Veress needle was also associated with an increased incidence of failed entry, extraperitoneal insufflation, and omental injury.<sup>9</sup> The low rate of reported complications associated with laparoscopic entry and the small number of participants within the included studies may account for the lack of significant difference in major vascular and visceral injury between entry techniques.<sup>9</sup>

#### *Direct trocar entry technique*

The suggested advantage of the direct trocar entry technique of entry is the avoidance of complications related to the use of the Veress needle: failed pneumoperitoneum, preperitoneal insufflation, intestinal insufflation, or the more serious carbon dioxide (CO<sub>2</sub>) embolism. Laparoscopic entry is initiated with only one blind step (i.e., the trocar), instead of three steps (i.e., Veress needle, insufflation, trocar).<sup>10</sup> The direct entry method is faster than any other method of entry; however, it is the least performed laparoscopic technique in clinical practice today.<sup>11</sup> The technique begins with an infraumbilical skin incision that is sufficiently wide to accommodate the diameter of a sharp trocar/cannula system. The anterior abdominal wall must be adequately elevated by hand, and the trocar is inserted directly into the cavity, aiming toward the pelvic hollow. As an alternative, the abdominal wall is elevated by pulling on two towel clips placed 3 cm on both sides of the umbilicus, and the trocar is inserted at a 90° angle.<sup>12</sup> The Cochrane database of systematic reviews 2012 concluded that there was an advantage in using a direct-entry technique in comparison to Veress needle entry with regard to failed entry, extraperitoneal insufflation, and omental injury.<sup>9</sup>

#### *Optical (direct vision) access technique*

The optical access technique (also called the direct vision technique) accesses the peritoneal cavity with specialized trocars or devices that have a transparent tip, which allows each layer of the

abdominal wall to be visualized as it is being traversed with a 0° laparoscope. These devices are typically used for primary port placement after Veress needle abdominal insufflation or secondary port placement after establishing the pneumoperitoneum. The procedures of this technique are to establish the pneumoperitoneum first, and then to make an incision (0.5–1 cm) in the skin at the appropriate port site. The optical trocar/device system is placed into the incision with the 0° scope placed perpendicularly to the abdominal wall. Gentle downward pressure on the abdominal wall is applied with the device while viewing each successive layer of the abdominal wall. When a rush of gas from the peritoneal cavity is heard, the proper depth has been reached. The camera is removed and the trocar is withdrawn slightly and the cannula is advanced 1–2 cm. The trocar is removed and the laparoscope reinserted. Visualization of the omentum confirms correct placement of the device in the peritoneal cavity.<sup>13</sup>

#### *Radially expanding access system*

The radially expanding access system (Step; InnerDyne, Sunnyvale, CA, USA) was introduced in 1994. It consists of a 1.9 mm Veress needle surrounded by an expanding polymeric sleeve. The abdomen may first be insufflated by using the Veress needle. The needle is removed, and the sleeve acts as a tract through the abdominal wall that can be dilated up to 12 mm by inserting a blunt obturator with a twisting motion. The Cochrane database of systematic reviews 2012 concluded that no evidence existed to suggest that radially expanding trocars are safe in reducing major complications during primary or secondary port placement. However, a significant reduction in trocar site bleeding was noted with their use.<sup>9,14–17</sup>

### Access locations

#### *Umbilical point*

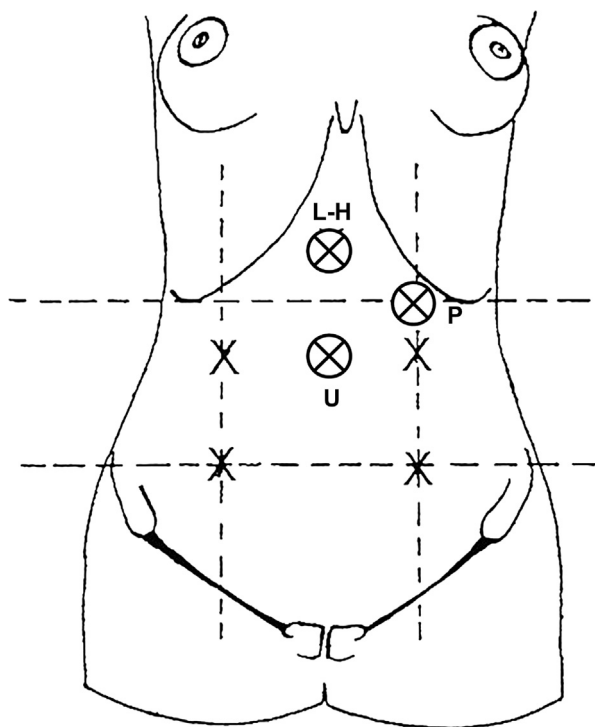
The umbilical point is the typical area where the Veress needle is inserted (Fig. 1), with or without lifting the anterior abdominal wall. Alternative sites for insertion should be considered for patients who are suspected of having periumbilical adhesions or after three failed insufflation attempts to establish a pneumoperitoneum.<sup>18</sup>

#### *Left upper quadrant or Palmer's point*

The left upper quadrant or Palmer's point was developed by Raoul Palmer who advocated the insertion of the Veress needle at a range of 3 cm below the left subcostal in the midclavicular line (Fig. 1).<sup>19</sup> This technique should be considered for patients with previous laparotomy or obesity, and for exceptionally thin patients. In extremely thin patients with a prominent sacral promontory and android pelvis, the great vessels lie 1–2 cm below the umbilicus, but in obese women, the umbilicus is shifted caudally to aortic bifurcation.<sup>20,21</sup> Gastric decompression is important in managing these patients; hence, the Veress needle should be introduced perpendicularly to the skin. Patients with previous splenic or gastric surgery, hepatosplenomegaly, portal hypertension, and gastropancreatic masses should be excluded.<sup>22</sup> Tulikangas et al.<sup>22</sup> noted a correlation between body mass index (BMI), the distance between various intra-abdominal organs, and the insertion site. After establishing the pneumoperitoneum, the primary trocar of various diameters and shapes is introduced at the same site as the Veress needle, followed by insertion of the accessory cannulas under direct vision.

#### *Middle upper abdomen (Lee-Huang point)*

The middle upper abdomen (Lee-Huang point) lies centrally between the xiphoid process and the umbilicus (Fig. 1). In 2001, this technique was published by Lee et al.<sup>23</sup> who used this point for the Veress needle and primary port insertion as an alternative portal for laparoscopy and operative pelviscopy in 188 women who



**Fig. 1.** The access points for abdominal entry in laparoscopic surgery. L-H = Lee-Huang point; P = Palmer's point; U = umbilical point.

were at high risk for subumbilical adhesions because of previous abdominal surgeries or because of a history of gynecologic cancer.<sup>23</sup> During this surgery no complications occurred in 98.4% of 188 patients and none of the procedures was converted to a laparotomy. Two omentum injuries from primary port insertion were desiccated with bipolar electrocoagulation and a colon injury was repaired with laparoscopic sutures. Lee et al<sup>23</sup> concluded that the Lee-Huang point is effective for women who had previous abdominal surgery or gynecologic malignancy. In patients with large pelvic pathology or malignancy, the reasons for using this technique for the first trocar and major trocar are: (1) the first trocar at the Lee-Huang point can overcome and avoid obstacles from adhesions resulting from a previous low-midline incision and an overcrowded operative field caused by a large uterus; (2) by using the Lee-Huang point for the telescope entrance, it is unnecessary to change the telescope access from the umbilicus to right or left upper quadrant because surgeons will have a higher view than what is provided by conventional umbilical telescope access; and (3) the Lee-Huang point provides central vision rather than the lateral vision of the operative field described by other authors. Central vision is important because uterine myoma can be located in any portion of the uterus and only central vision allows surgeons to have easy access to both sides of the pelvis.<sup>23–28</sup>

The contraindication to using the Lee-Huang point insertion is a patient who has had previous surgery at the supra-umbilical region. In case the surgeon cannot access the Lee-Huang point or if there is a problem with using the Lee-Huang point, alternative choices are to change to the Palmer's point, the open insertion technique, or the optical (direct vision) access technique.<sup>23–28</sup>

#### Veress needle insertion

In most patients, the inferior crease of umbilicus is the best site for incision.<sup>29</sup> However in obese patients, the transumbilical incision is preferred because this area has the least thickness of fat.<sup>18,30</sup> The angle

of Veress needle insertion consequently differs from 45° in nonobese women to 90° in extraordinarily obese women.<sup>31,32</sup> Cochrane database of systematic reviews 2012 concluded that not lifting the abdominal wall prior to inserting the Veress needle was associated with a significantly lower rate of failed entry, compared to lifting the wall [odds ratio (OR), 4.44; 95% CI 2.16–9.13], and no advantage was noted in vascular or visceral complications.<sup>9</sup> The requisite length of Veress needle to reach the peritoneal cavity should be estimated.<sup>33</sup>

For nonobese patients, the Veress needle is grasped above the measured distance and inserted through an incision at a 45° angle toward the pelvis cavity while carefully avoiding lateral deviation. Two “pops” should be felt. The first “pop” occurs when the needle passes through the abdominal fascia and the second “pop” occurs as the needle passes through the parietal peritoneum. When the needle passes through the peritoneum and enters the peritoneal space, the displaced hub of the needle will “click” as the protective sheath recoils to cover the end of the needle.

Studies have reported the complication rates in regard to the number of Veress needle insertion attempts, as follows: 0.8–16.3% for one attempt; 16.31–37.5% for two attempts; 44.4–64% for three attempts; and approximately 84.6–100% for more than three attempts. Other complications were extraperitoneal insufflation, omental and bowel injuries, and failed laparoscopy.<sup>34</sup>

#### Safety Test

Multiple alternatives are offered to confirm Veress needle placement; however, no trials have shown a portentous usage of one method over another method.<sup>35</sup> These include one of the following.

##### Irrigation and aspiration test

The irrigation and aspiration test is the most widely used safety test. It is performed with the aid of an empty syringe or a syringe that contains physiological saline. This test consists of three steps. The first step is aspiration, which should not produce air, liquid, or pus, and thus ascertain the absence of vascular, urinary, or intestinal perforation. In the second step, 20 cc. of air or fluid is injected; there should be no resistance or fluid aspirated. This is an easy method for confirming no contact with intra-abdominal viscera or adhesions. The third step is the attempt to reaspirate the injected air or liquid. Reaspiration should be unattainable to confirm the proper intraperitoneal placement of the Veress needle. If any fresh blood or fecal fluid is aspirated in the syringe, the surgeon should not remove the Veress needle. An emergency laparotomy is then required. Leaving the Veress needle in position helps to localize the punctured area after laparotomy and facilitates subsequent hemostasis.<sup>35–39</sup>

##### Hanging drop test

In the hanging drop test, a few drops of physiological saline should be poured over the Veress needle and the abdominal wall should be slightly lifted. If the tip of the Veress needle is inside the abdominal cavity, the saline should be drained inside because of the abdominal negative pressure; if the needle point is misplaced, then the hanging drop test will be negative.<sup>35–39</sup>

##### Gas insufflation test

In the gas insufflation test, the intraperitoneal pressure should be  $\leq 10$  mmHg. One of the largest observational study concluded that the confirmation of low intraperitoneal pressure method was the most reliable method to confirm Veress needle placement.<sup>35–39</sup>

##### Trocar access

The primary trocar admission is recommended after the pneumoperitoneum is created by air insufflation and after adequate

intra-abdominal pressure has been achieved. There is a controversy in defining an “adequate,” “appropriate,” or “sufficient” pneumoperitoneum. It has traditionally been defined by an arbitrary volume of 1–4 L of CO<sub>2</sub> or an arbitrary intra-peritoneal pressure of 10–15 mmHg. Richardson and Sutton<sup>34</sup> undertook a prospective study of 836 patients undergoing laparoscopy to determine the complications associated with the first entry by using the volume technique ( $n = 291$ ) and the pressure technique ( $n = 335$ , median pressure 14 mmHg) as the end points. At all levels of operator experience, the average volume of CO<sub>2</sub> used in the pressure technique group was significantly greater than with the volume technique, but the complication rate in the pressure technique group was lower than in the volume technique group. Thus the authors suggested that the pressure technique should be universally adopted.<sup>34</sup>

At this point, removal of the Veress needle is followed by primary trocar insertion. When passing through the fascia and protruding into abdominal cavity, the surgeon should have a typical tactile sensation. Accurate trocar insertion depends on a proper superficial incision, trocar axis, and correct intra-abdominal pressure. In some patients, lifting the abdominal wall by hand or with an Allis forceps could be helpful. However some studies show that elevation of the anterior abdominal wall at the time of primary trocar insertion is not routinely recommended because it does not avoid visceral or vessel injury.<sup>31–33,40</sup> After insertion, the position of the trocar must be confirmed by introducing the laparoscope and examining the pelvic cavity.

## Conclusion

In gynecologic surgery, laparoscopy is superior to laparotomy in diminishing minor complications, postoperative pain, and length of hospitalization stay. Many techniques have been introduced to eliminate laparoscopic entry complications; however, not a single technique has been proven to eliminate this complication. The open entry technique is associated with a significant reduction of failed entry attempts, compared to the closed entry technique; however, there is no difference in the incidence of visceral or vascular injury. In addition, the use of the Veress needle was associated with an increased incidence of failed entry, extraperitoneal insufflation, and omental injury. Compared to using the Veress needle entry, the direct entry technique has more advantages in terms of failed entry, extraperitoneal insufflation, and omental injury. No evidence indicates that radially expanding trocars are safe in reducing major complications during primary or secondary port placement. However, a significant reduction in trocar site bleeding was noted with their use. The middle upper abdomen (i.e., Lee-Huang point) laparoscopic entry has a lot of advantages for the operative laparoscopy, especially for large pelvic pathology and gynecologic malignancy cases because of the wide abdominal cavity access, proper visual angle, and increased working distance. The angle of the Veress needle insertion ranges from 45° in nonobese women to 90° in extraordinarily obese women. The high intraperitoneal pressure entries (HIP), with a range of 20–25 mmHg, minimize the risk of vascular injury and does not adversely affect cardiopulmonary function in healthy women. The various Veress needle safety tests are not a sensitive indicator of the proper placement of the Veress needle. The Veress intraperitoneal pressure (i.e., <10 mmHg) is a reliable indicator of accurate Veress needle intraperitoneal placement. The elevation of anterior abdominal wall for placement of a Veress needle increases the risk of failed entry, and has no advantages in regard to vascular or visceral complications. To prevent and decrease complications, surgeons should continue to increase their knowledge of anatomy, their training, and their experience.

## References

- Chapron C, Fauconnier A, Goffinet F, Breart G, Dubuisson JB. Laparoscopic surgery is not inherently dangerous for patients presenting with benign gynecologic pathology: results of a meta-analysis. *Hum Reprod*. 2002;17:1334–1342.
- Medeiros LR, Fachel JMG, Garry R, Stein AT, Furness S. Laparoscopy versus laparotomy for benign ovarian tumors. *Cochrane Database Syst Rev* 2005;(3): CD004751. Pup2. DOT:10.1002/14651858.
- Magrina J. Complications of laparoscopic surgery. *Clin Obstet Gynecol*. 2002;45: 469–480.
- Jansen FW, Kolkman W, Bakkuim EA, de Kroon CD, Trimbos-Kemper TCM, Trimbos JB. Complications of laparoscopy: an inquiry about closed versus open-entry technique. *Am J Obstet Gynecol*. 2004;190:634–638.
- Fuller J, Scott W, Ashar B, Corrado J. *Laparoscopic trocar injuries: a report from a US FDA Center for Devices and Radiological Health (CDRH) Systematic Technology Assessment of Medical Products (STAMP) Committee*. 2005 Aug 8:1–14.
- Krishnakumar S, Tambe P. Entry complications in laparoscopic surgery. *J Gynecol Endosc Surg*. 2009;1:4–11.
- Hasson HM, Rotman C, Rana N, Kumari NA. Open laparoscopy: 29-year experience. *Obstet Gynecol*. 2000;96:763.
- Long JB, Giles DL, Cornella JL, Magtibay PM, Kho RM, Magrina JF. Open laparoscopic access technique: review of 2010 patients. *JLS*. 2008 Oct–Dec;12: 372–375.
- Ahmad G, O'Flynn H, Duffy JM, Phillips K, Watson A. Laparoscopic entry techniques. *Cochrane Database Syst Rev*. 2012 Feb;15(2):CD006583.
- Catarci M, Carlini M, Gentileschi P, Santoro E, for the Lap Group Roma. Major and minor injuries during the creation of pneumoperitoneum: a multicenter study on 12,919 cases. *Surg Endosc*. 2001;15:566–569.
- Byron JW, Markenson G, Miyazawa K. A randomized comparison of Veress needle and direct trocar insertion for laparoscopy. *Surg Gynecol Obstet*. 1993;177:256–262.
- Borgatta L, Gruss L, Barad D, Kaali SG. Direct trocar insertion vs Veress needle use for laparoscopic sterilization. *J Reprod Med*. 1990;35:891–894.
- String A, Berber E, Foroutani A, et al. Use of the optical access trocar for safe and rapid entry in various laparoscopic procedures. *Surg Endosc*. 2001;15:570.
- Yim SF, Yuen PM. Randomized double-masked comparison of radially expanding access device and conventional cutting tip trocar in laparoscopy. *Obstet Gynecol*. 2001;97:435–438.
- Lam TY, Lee SW, So HS, Kwok SP. Radially expanding trocars: a less painful alternative for laparoscopic surgery. *J Laparoendosc Adv Surg Tech A*. 2000;19: 269–273.
- Bhoyrul S, Payne J, Steffes B, Swanson L, Way LW. A randomized prospective study of radially expanding trocars in laparoscopic surgery. *J Gastrointest Surg*. 2000;4:392–397.
- Feste JR, Bojahr B, Turner DJ. Randomized trial comparing a radially expandable needle system with cutting trocars. *J Soc Laparosc Endosc Surg*. 2000;4:11–15.
- Brill AJ, Cohen BM. Fundamentals of peritoneal access. *J Am Assoc Gynecol Laparosc*. 2003;10:287–297.
- Palmer R. Safety in laparoscopy. *J Reprod Med*. 1974;13:1–5.
- Hurd WW, Bude RO, De Lancey JO, Pearl ML. The relationship of the umbilicus to the aortic bifurcation: complications for laparoscopic technique. *Obstet Gynecol*. 1992;80:48–51.
- Hurd WW, Bude RD, De Lancey JO, Gauvin JM, Aisen AM. Abdominal wall characterization with magnetic resonance imaging and computed tomography: the effect of obesity in the laparoscopic approach. *J Reprod Med*. 1991;36: 473–476.
- Tulikangas RK, Nicklas A, Falcone T, Price LL. Anatomy of the left upper quadrant for cannula insertion. *J Am Assoc Gynecol Laparosc*. 2000;7: 211–214.
- Lee CL, Huang KG, Jain S, Wang CJ, Yen CF, Soong YK. A new portal for gynecologic laparoscopy. *J Am Assoc Gynecol Laparosc*. 2001;8:147–150.
- Lee CL, Huang KG. Total laparoscopic radical hysterectomy using Lee-Huang portal and McCartney transvaginal tube. *J Am Assoc Gynecol Laparosc*. 2002;9: 536–540.
- Lee CL, Huang KG, Smita J, Lee PS, Soong YK. Comparison of laparoscopic and conventional surgery in the treatment of early cervical cancer. *J Am Assoc Gynecol Laparosc*. 2002;9:481–487.
- Lee CL, Huang KG, Wang CJ, et al. Radical laparoscopic surgery for carcinoma of the cervical stump. *J Am Assoc Gynecol Laparosc*. 2000;7:241–244.
- Lee CL, Huang KG, Wang CW. New approaches in laparoscopically assisted radical vaginal hysterectomy. *Int Surg*. 1997;82:266–268.
- Lee CL, Huang KG, Lai YM, et al. Ureteral injury during laparoscopically assisted radical vaginal hysterectomy. *Hum Reprod*. 1995;10:2047–2049.
- Rosen DM, Lam AM, Chapman M, Carlton M, Cario GM. Methods of creating pneumoperitoneum: a review of techniques and complications. *Obstet Gynecol Surv*. 1998;53:167–174.
- Molloy D, Kallou PD, Cooper M, Nguyen TV. Laparoscopic entry: a literature review and analysis of techniques and complications of primary port entry. *Aust NZJ Obstet Gynaecol*. 2002;42:246–254.
- Roy GM, Bazzurini L, Solima E, Luciano AA. Safe technique for laparoscopic entry into the abdominal cavity. *J Am Assoc Gynecol Laparosc*. 2001;8: 519–528.



32. Corson SL, Brooks PG, Soderstrom RM. Safe technique for laparoscopic entry into the abdominal cavity [Letter]. *J Am Assoc Gynecol Laparosc*. 2002;9:399–401.
33. Hill DJ, Maher PJ. Direct cannula entry for laparoscopy. *J Am Assoc Gynecol Laparosc*. 1996;4:77–79.
34. Richardson RF, Sutton CJG. Complications of first entry: a prospective laparoscopic audit. *Gynaecol Endosc*. 1999;8:327–334.
35. Teoh B, Sen R, Abbott J. An evaluation of four tests used to ascertain Veress needle placement at closed laparoscopy. *J Minim Invasive Gynecol*. 2005;12:153–158.
36. Fear RE. Laparoscopy: a valuable aid in gynecologic diagnosis. *Obstet Gynecol*. 1968;31:297–309.
37. Lacey CG. Laparoscopy: a clinical sign for intraperitoneal needle placement. *Obstet Gynecol*. 1976;47:625–627.
38. Marret H, Harchaoui Y, Chapron C, Lansac J, Pierre F. Trocar injuries during laparoscopic gynaecological surgery. Report from the French Society of Gynecological Laparoscopy. *Gynaecol Endosc*. 1998;7:235–241.
39. Semm K, Semm I. Safe insertion of trocars and Veress needle using standard equipment and the 11 security steps. *Gynaecol Endosc*. 1999;8:339–347.
40. Nezhat FR, Silfen SL, Evans D, Nezhat C. Comparison of direct insertion of disposable and standard reusable laparoscopic trocars and previous pneumoperitoneum with Veress needle. *Obstet Gynecol*. 1991;78:148–150.