



Original article

A modified three-port “hidden scars” surgical approach in gynecology: A surgeon's experience of an initial 72 cases

Felix Wu Shun Wong^{a,*}, Eric Tat Choi Lee^b^a School of Women's and Children's Health, University of New South Wales, Sydney, New South Wales, Australia^b Canossa Hospital, Hong Kong SAR, China

ARTICLE INFO

Article history:

Received 13 October 2013

Received in revised form

7 February 2014

Accepted 7 February 2014

Available online 16 June 2014

Keywords:

gynecology

hidden scars

laparoscopy

surgical approach

ABSTRACT

Objective: The study objectives were to determine the surgical outcomes of a personal series of gynecological patients treated with a modified three-port “hidden scars” surgical approach (HS surgical approach) for the treatment of benign gynecological diseases.

Study design: This was a retrospective series performed by one of the study authors FW to analyze 72 women treated with a modified three-port HS approach for the treatment of benign gynecological diseases from January 2013 to August 2013.

Results: Patients' characteristics, pathology, outcome, and gynecologic procedures performed using this HS approach are presented. The surgical procedures included 34 laparoscopic adnexal ovarian and tubal surgeries, 28 laparoscopic hysterectomy (including pelvic lymphadenectomy for the treatment of uterine cancer in 1 patient), eight laparoscopic myomectomy, one laparoscopic adhesiolysis, and one laparoscopic excision of severe pelvic endometriosis. Laparoscopic myomectomy and excision of advanced pelvic endometriosis took longer time to perform with this approach, but there was no significant difference in the amount of blood loss and length of stay in the hospital. There was no perioperative complication in this personal series.

Conclusion: The HS approach in gynecological surgery is feasible, safe, and reproducible when applied in women with gynecological diseases. The operation time, length of stay, and outcome would be comparable to conventional laparoscopic surgery.

Copyright © 2014, The Asia-Pacific Association for Gynecologic Endoscopy and Minimally Invasive Therapy. Published by Elsevier Taiwan LLC. All rights reserved.

Introduction

Scars are the hallmarks of surgery, and therefore, no surgery is scarless. Even the single-incision laparoscopic surgery (SILS) technique, which is the latest innovation in the advancement of endoscopy, produces scarring. It only requires a single incision, but produces a reduced number of scars that are not obvious to others except for the doctor and the patient. SILS works by replacing the three- to four-portal incisions of conventional laparoscopy with a single 2–3-cm incision at the umbilicus. The entire surgical procedure is completed through this single incision. This laparoscopic approach aims at eliminating the use of accessory ports and minimizing the potential complications related to those ports, and provides a safe, “scarless” and esthetic option.^{1,2} Patients often

enjoy speedy postoperative recovery times and are impressed by the “scarless” technique.

However, many surgeons had found it clumsy to perform this type of surgery because of its technical limitations. Even though modified laparoscopic instruments and flexible cameras have been developed to facilitate the operative performance, additional instrumentation is costly and new techniques to overcoming this intrinsic difficulties are needed to make SILS more applicable.

SILS also requires the use of specially designed umbilical port devices developed by various medical equipment manufacturers. These devices enable gynecologists to achieve and complete their SILS. However, they impose additional costs without any documented operative advantages. Using the same concept, some surgeons used multiple conventional trocars placed at the umbilicus to perform single-site multiple incisions laparoscopic surgery, yet they encountered the same technical difficulties as with SILS. In this paper, FW reports and shares his experience of a modified three-port “hidden scars” (HS) laparoscopic surgery technique. Using this approach, the author demonstrates that this new approach

Conflicts of interest: All contributing authors declare no conflicts of interest.

* Corresponding author. School of Women's and Children's Health, University of New South Wales, Sydney, New South Wales, Australia.

E-mail address: fwong3@hotmail.com.hk (F.W.S. Wong).

<http://dx.doi.org/10.1016/j.gmit.2014.05.003>

2213-3070/Copyright © 2014, The Asia-Pacific Association for Gynecologic Endoscopy and Minimally Invasive Therapy. Published by Elsevier Taiwan LLC. All rights reserved.

possesses the technical advantages of both SILS and conventional laparoscopy.

Surgical techniques

Ports

The patient was positioned in a lithotomy position with her legs held apart, similar to that while performing a conventional laparoscopy. The key to this approach is to position the port incisions on the abdomen that can hardly be noticeable. This modified three-port HS laparoscopic approach is described as follows:

The positions of the three ports

A small 5-mm incision is made at one side (8 o'clock) of the umbilicus, followed by a direct entry of an optic tip trocar and cannula under direct laparoscopic vision as described previously by the same author.³ Another 5-mm trocar/cannula is introduced 0.5 cm apart, but at the other side (4 o'clock) of the umbilicus. An additional port is placed at the mid-suprapubic point just below the level of pubic hairline. If the insertion of the trocar above the hairline is deemed necessary for augmented triangulation in manipulation, a 3- or 5-mm trocar and cannula can be positioned over the left lower quadrant of the abdomen if a surgeon stands on the patient's left side. This side port using a 3-mm mini-port trocar and cannula can result in a smaller or almost invisible scar. The port positions of the laparoscope and operative instruments are shown in Fig. 1.

Instruments

A conventional straight laparoscope and operative instruments are used with this approach. No angulated instruments or flexible camera are required. A 5-mm laparoscope, preferably a 30° angled laparoscope, should be used to provide an angled view. This would minimize the risk of clashing with other operating instruments. However, it is worth noticing that the head of the portal cannula at the umbilicus should be small, to allow enough space between the laparoscope and the operating instrument in order to operate without any interference. At the time of specimen retrieval, it is also necessary to enlarge one of the 5-mm incisions at the umbilicus into a 10–12-mm incision, followed by an insertion of a blunt 10–12-mm trocar and cannula. This serves to allow the introduction of an Endobag for collection and retrieval of specimen, and for

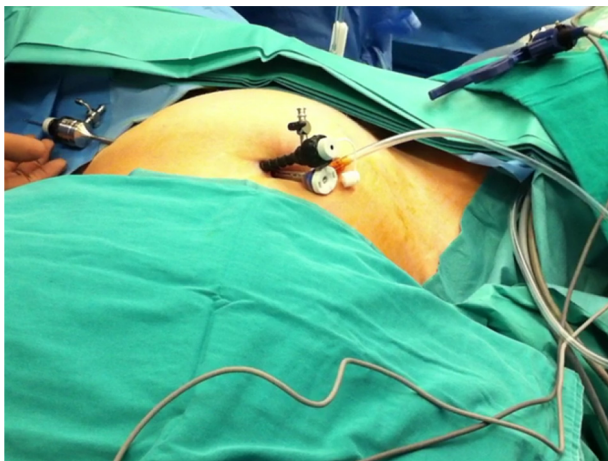


Fig. 1. The positions of two ports in the umbilicus and one in the left lower abdominal quadrant as described. Note the size of the two 5-mm cannula heads, which can sit comfortably next to each other.

inserting a 10-mm grasping forceps or a 12-mm electric morcellator for myomectomy and morcellation. When surgical suturing is required, the enlarged incision is also used for the introduction of needle and stitches.

The surgical steps used for the various gynecological conditions in this series were similar to those of conventional laparoscopic procedures such as ovarian cystectomy, salpingo-oophorectomy, myomectomy, and hysterectomy. The key points are briefly presented as follows:

Adnexal disease (salpingo-oophorectomy/oophorectomy/ovarian cystectomy)

Adnexal surgery was performed using this HS approach without the need for specialized instruments. Mobilization of the adnexal cyst or tumor was achieved using a uterine manipulator. At the same time, the operating instruments can work from the umbilical port, the low midline port, or a left lower quadrant port. The surgery was completed in a similar manner to that of conventional laparoscopy. The adnexal ovarian and tubal specimens were removed from the abdomen using an Endobag, which was inserted through a 10-mm cannula placed over an enlarged 5-mm port at the umbilicus. The 10-mm cannula can still allow the subsequent use of a 5-mm instrument by the addition of port-size reducer.

Myomectomy

The number of cases is small in this series because of the technical difficulty associated with surgery on large fibroid(s). If uterine size was larger than 12 weeks, it would be difficult to manipulate the fibroid if the position of the port was placed below the hairline. Cases that required a much higher lower port placement for instrument manipulation were excluded from series, because the scars would then become too conspicuous and would not fit into the concept of HS. After myomectomy, laparoscopic suturing using the V-lock suture facilitates an easy completion of two-layer myomectomy wound closure. The leiomyomas were then morcellated and removed piece by piece using a 12-mm electrical morcellator inserted through an enlarged umbilical port under direct visualization with a 5-mm laparoscope placed at the lateral port or an angled laparoscope over the suprapubic port.

Hysterectomy

In this series, laparoscopy-assisted vaginal hysterectomy [LAVH ± bilateral salpingo-oophorectomy (BSO)] was performed in the 28 patients who underwent hysterectomy. No technical difficulty was encountered while performing these procedures. LAVH was successfully performed and the uterus was removed through the vagina with or without vaginal morcellation. LAVH is most suitable using this approach because it did not require laparoscopic suturing of the vaginal vault as in the case of total laparoscopic hysterectomy (TLH) or morcellation of the uterus as in the case of laparoscopic subtotal hysterectomy (LSH). Technically, with the HS approach, both TLH and LSH can be performed, but they were not done in this series.

Results

Laparoscopic surgery using the HS approach was performed in 72 women. The patients' characteristics, pathology, gynecologic procedures, and outcomes are listed in Table 1.

Thirty-four patients underwent laparoscopic adnexal surgery, including 20 for salpingo-oophorectomy and 14 for ovarian cystectomy. Twenty-eight patients had LAVH ± BSO and eight patients

Table 1
Characteristics of patients, pathology, and surgical outcome in this series.

HSS for	No. of patients	Age (median)	BMI (mean)	Pathology (no. of patients)	OT (mean), min	Blood loss (mean) in mL	Hospital stay, d (mean)	Outcome
Adnexal surgery	34	38.0	23.9	Endometrioma (14), cystadenoma (11), dermoid cysts (7), paraovarian cyst (2)	45.1	35.8	1.3	No complications
Hysterectomy	28	50.6	23.7	Fibroids (14), adenomyoma (4), DUB (6), polyp (3), cancer of the uterus (1)	82	77.8	2.4	No complications
Myomectomy	8	47	28.2	Single fibroid (5), multiple fibroids (3)	94.5	87.5	2.5	No complications
Miscellaneous	2	38	20.2	Pelvic adhesion (1), pelvic endometriosis (1)	175	205	2.5	No complications
Total (mean)	72	(43.8)	(24.1)	—	—	(66.5)	(1.9)	—

BMI = body mass index; DUB = dysfunctional uterine bleeding; HSS = hidden scar surgery; OT = operation time.

had laparoscopic myomectomy. One patient had laparoscopic adhesiolysis and one had laparoscopic excision of severe pelvic endometriosis. All surgeries were completed successfully using this approach.

No intraoperative morbidity or complications were recorded and the average hospital stay was less than 48 hours. At follow-up visits, no complications were recorded and cosmesis was excellent.

Discussion

Minimally invasive surgery plays an increasing role in the treatment of many gynecological diseases. The conventional laparoscopic surgery using three to four ports is now considered by some to be unnecessary for many women with less advanced stage of gynecological diseases. SILS is a rapidly developing field, which may mark a new frontier in laparoscopy.¹ The increasing efforts to decrease port-associated morbidity and to improve cosmesis in laparoscopic surgery have further advanced this new approach to surgery so as to minimize the number and size of ports required for these procedures. This approach to surgery can further improve laparoscopic surgical outcome with less postoperative pain, less visible port size, less port-related complications, less wound-related complications, no visible scar, etc.

Despite the development and the rising trends of SILS, it has yet to become a standard surgical technique in gynecologic surgery for several reasons: (1) Clashing and “sword fighting” of the instruments due to the limited space at the single entry point; (2) use of newly designed instruments that might require retraining; (3) more demand for advanced skills for performing difficult surgeries; (4) steep and long learning curve due to high level of skill and technical ability required; (5) loss of angulation for suturing, separation of tissues, and achievement of hemostasis. All these can lead to a difficult and demanding procedure. Despite its reported successful applications in gynecology, short-term or long-term complications might still occur.⁴

Using the single-port HS concept in SILS, this paper describes a modified three-port approach, with two ports in the umbilicus and one port hidden elsewhere in the body. For example, the second operating port was placed well below the pubic hairline, and together with the use of the port over the umbilicus all body scars will become entirely hidden after complete healing of the wound. Any procedure using this approach can be performed with conventional instruments at an angulation similar to other laparoscopic surgeries with or without the assistance obtained through manipulation of the target organ. This HS approach will not only shorten the learning curve and reduce the difficulties encountered in SILS, but will also provide similar patient outcomes. The use of multiple trocars around the umbilicus (with separate skin and fascia incisions) in this technique also has other advantages: (1) closure of the separate smaller abdominal wounds (5 mm) is much easier and faster than those used in the SILS approach as no suturing is required on most occasions; (2) potential risks of wound dehiscence, wound infection, hernia formation, and keloid formation are likely to be reduced by

using the much smaller wounds; (3) it can be easily performed by a single surgeon even if help from an assistant is not available; and (4) the cost involved in the use of conventional trocars is far less and it can be a big cost-saving method as compared with SILS.

The technical feasibility has been demonstrated in many gynecological procedures in this series, including ovarian cystectomy, salpingo-oophorectomy, myomectomy, and hysterectomy. As many of the necessary instruments are at least 10–12 mm in diameter (e.g., myomectomy clamps, morcellator, and the cannula for the introduction of the specimen retrieval Endobag), it is not infrequent that one of the 5-mm umbilical ports would have to be enlarged to a 10-mm incision to allow for the introduction of a 10–12-mm trocar and cannula. Even if one of the umbilical wounds is enlarged with this surgical approach, the scar is still unrecognizable after the procedure (Fig. 2).

However, there are a few techniques to be elaborated on and some relatively difficult situations that need to be addressed and further evaluated in using this new surgical approach. These are as follows:

- 1) The laparoscope often follows behind the operating instruments and thus the laparoscopic view is far away from the operating field (Fig. 3A). This is a disadvantage to some inexperienced surgeons.
- 2) The use of a small-sized 5-mm laparoscope can pose some difficulty in maintaining a consistently good visual field as its small lens could be easily contaminated by blood or smoke, resulting in blurred vision. This necessitates cleaning of the lens more often as compared with the use of a 10-mm laparoscope with its larger lens (Fig. 3B).
- 3) All the umbilical trocars and cannulas should carry small-sized heads to avoid clashing over the small space at the umbilicus.
- 4) Clashing and hindrance of the laparoscope on the operating instrument can still be a problem. However, the use of a 30° 5-

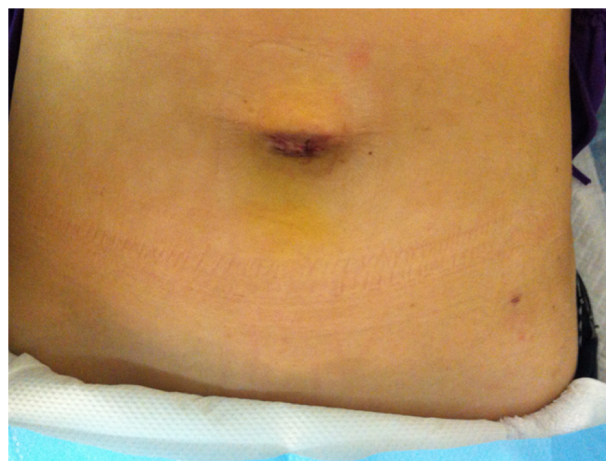

Fig. 2. Esthetic appearance of scars at the umbilicus and left lower quadrant in a patient after surgery with a modified three-port hidden scar surgical approach.

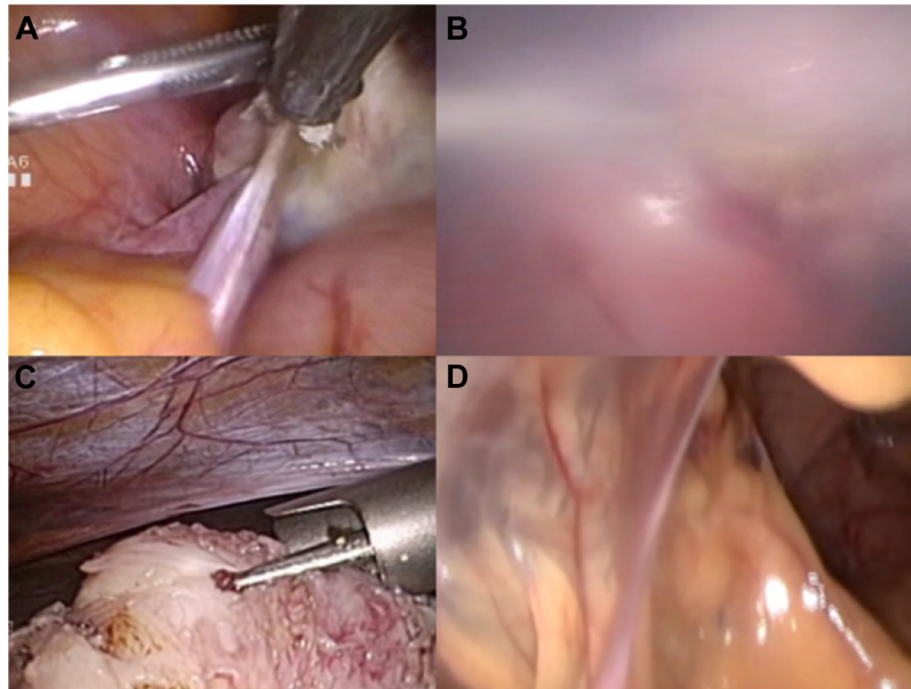


Fig. 3. Difficult technical issues. (A) Hard to assess operative field from the laparoscope looking at the same direction with zero-degree laparoscope. (B) Smoke obscuring the operating view during monopolar diathermy. (C) Morcellation of fibroid under direct laparoscopic vision. (D) Severe pelvic adhesion in a difficult situation.

- mm scope will facilitate the maneuverability of the operating instruments, and therefore avoids clashing of instruments. Nevertheless, a 30° lens is not indispensable in using this approach as many procedures in this paper were successfully performed using a 0° 5-mm scope. Despite the unavailability of a 90° optic adaptor for the light cable in this study, all procedures studied were accomplished without undue clashing of instruments. However, experience in using such approach is essential if a procedure is to be performed smoothly and safely.
- 5) In this approach, a 10-mm port should always be positioned at the umbilicus if it is required, so as to avoid making a large unsightly scar at the abdomen and that would defeat the purpose of this “HS” surgery. Placing the morcellator over the umbilicus to remove large fibroid or uterine specimen should be done with care under direct laparoscopic monitoring from the lateral abdominal port (Fig. 3C). Somehow, an enlargement of an umbilical port to 10, 12, or even 15 mm to accommodate a morcellator would carry a potential risk of asymmetrical umbilical scarring in using the portal positions as described in this approach. In such an event, one could consider using alternative positions for the two umbilical ports to obtain a better cosmetic result, for example by changing one port to a 12 o'clock instead of a 4 or 8 o'clock position.
 - 6) Laparoscopic suturing becomes easier with a vertical myomectomy wound, and with the use of V-lock sutures to close the uterine wound.
 - 7) Similar to other three-port laparoscopic surgeries, difficult surgeries in this approach such as severe pelvic adhesions and advanced pelvic endometriosis are feasible as demonstrated in this series (Fig. 3D).
 - 8) There are situations when this approach might need to be modified using a second operating port inserted at a site above the pubic hairline. For example, in cases such as large fibroid, large ovarian cysts, obliterated Pouch of Douglas, multiple dense pelvic adhesions where the operating fields are outside the pelvis. An operating port inserted below the hairline in these situations would cause great difficulty in tackling the pathology.

Despite an initial attempt at a HS approach, conversion to conventional laparoscopy using three to four ports in difficult situations would still be appreciated by our patients especially if the procedure can be accomplished easily and safely.

- 9) If there are suspected adhesions at the umbilical site or intrinsic fascial weakness at the umbilicus, multiple incisions as used in this approach might lead to unexpected bowel injury or hernia formation. This is a relative contraindication for this HS approach.

The limitations of this personal series are its small number of patients, noncomparative design, single-surgeon experience, and biased selection of cases in its early development that would not have revealed difficulties and complications of some surgeries such as difficult cases of myomectomy, deep infiltrating endometriosis, and TLH. More prospective randomized studies comparing the outcome of single-port laparoscopic surgery (SILS), standard three to four ports, and modified three-port HS surgery should be performed to assess the value of this particular surgical approach. For the time being, this HS surgery approach seems to offer an advantage to surgeons with its familiar field of view and instruments similar to those used in conventional laparoscopy. Technically, it stands between standard laparoscopy and SILS in the armamentarium of minimal access surgery. This HS surgery can be considered an evolving surgical technique, and it still has a significant way to go before it becomes mainstream.

References

1. Fader AN, Rojas-Espaillet L, Ibeanu O, Grumbine FC, Escobar PF. Laparoendoscopic single-site surgery (LESS) in gynecology: a multi-institutional evaluation. *Am J Obstet Gynecol.* 2010;203:501.e1–501.e6.
2. Behnia-Willison F, Foroughinia L, Sina M, McChesney P. Single incision laparoscopic surgery (SILS) in gynaecology: feasibility and operative outcomes. *Aust N Z J Obstet Gynaecol.* 2012;52:366–370.
3. Wong WSF. A safe optically guided entry technique using Endopath Xcel Trocars in laparoscopic surgery: a personal series of 821 patients. *Gynecol Minim Invasive Ther.* 2013;2:30–33.
4. Park JY, Kim TJ, Kang HJ, et al. Laparoendoscopic single site (LESS) surgery in benign gynecology: perioperative and late complications of 515 cases. *Eur J Obstet Gynecol Reprod Biol.* 2013;167:215–218.