



## Case report

# Single-port access laparoscopic re-staging with bilateral salpingo-oophorectomy and bilateral pelvic lymph node dissection for endometrial cancer



Xiaohui Ong<sup>a</sup>, Elisa Koh<sup>b</sup>, Timothy Yong Kuei Lim<sup>b, c, \*</sup>

<sup>a</sup> Department of Obstetrics and Gynaecology, Kerdang Kerbau Women's and Children's Hospital, Singapore

<sup>b</sup> Department of Gynaecological Oncology, KK Women's and Children's Hospital, Singapore

<sup>c</sup> Pre-Invasive Disease and Screening Unit, Kerdang Kerbau Women's and Children's Hospital, Singapore

## ARTICLE INFO

## Article history:

Received 12 December 2013

Received in revised form

29 January 2014

Accepted 21 February 2014

Available online 10 November 2014

## Keywords:

endometrial cancer

laparoscopy

single port surgery

## ABSTRACT

Laparo-endoscopic single site surgery (LESS) is a relatively new technique that has been described in recent medical literature to be feasible in the management of benign gynaecological conditions. However, the use of this technique in the management of gynaecological cancers is still controversial. In this case report, we describe the first single port laparoscopic pelvic lymphadenectomy performed in Singapore. This involved a patient who was diagnosed with endometrial cancer after a vaginal hysterectomy for uterovaginal prolapse.

Copyright © 2014, The Asia-Pacific Association for Gynecologic Endoscopy and Minimally Invasive Therapy. Published by Elsevier Taiwan LLC. All rights reserved.

## Introduction

The use of laparo-endoscopic single-site surgery (LESS), also known as single-port surgery, has been reported previously for benign gynecological disorders.<sup>1–3</sup> It is, however, a relatively new and controversial technique for use in patients with gynecological cancers.<sup>4,5</sup> There have only been a few reports of the use of LESS for pelvic lymph node dissection (PLND).<sup>4,6–8</sup> We routinely perform systematic bilateral pelvic lymphadenectomy for all patients with a new clinical diagnosis of early stage Grade 1 or 2 endometrial cancer without any radiological evidence of distant metastases. This is usually achieved via conventional laparotomy, multiport laparoscopy, or Da Vinci robot-assisted surgery.

We report here our experience of the first single-port laparoscopic bilateral systematic PLND performed in Singapore. This involved a re-staging PLND for a patient who was diagnosed with endometrial cancer after a vaginal hysterectomy for uterovaginal prolapse.

## Case report

A 48-year-old Chinese woman presented with a lump at the introitus. She had been menopausal for a year and had no post-menopausal bleeding. On examination, she had a Grade 4 cystocele, Grade 4 uterovaginal prolapse, and a Grade 4 rectocele. There was no palpable abdominal mass or any other significant finding. A recently performed cervical smear was normal.

She underwent a vaginal hysterectomy and pelvic floor repair with sacrospinous fixation. However, the final histology revealed a Grade 1 well-differentiated endometrioid adenocarcinoma of the uterus involving the lower uterine segment. There was no myometrial or lymphovascular invasion. Both ovaries and fallopian tubes were conserved at the time of this first operation.

A postoperative computed tomography scan of her thorax, abdomen, and pelvis did not reveal any distant metastases. The patient was counseled on the need for bilateral salpingo-oophorectomy and bilateral PLND for surgical staging. The various routes of surgery, including laparotomy and laparoscopy, were discussed. She agreed to undergo a single-port laparoscopic bilateral salpingo-oophorectomy and bilateral systematic PLND. The intraoperative findings revealed a 4 cm left ovarian cyst and a normal-looking right ovary and fallopian tubes. However, both ovaries were adherent to the vaginal vault. There was no enlarged pelvic lymph node and the intraperitoneal survey was normal.

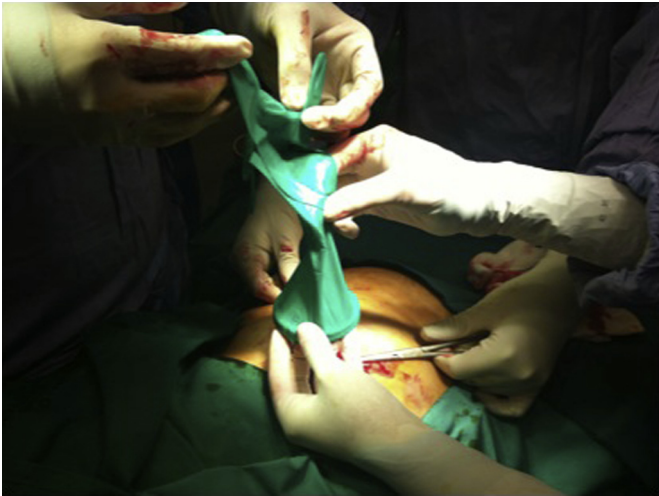Conflicts of interest: None declared.

\* Corresponding author. Department of Gynaecology Oncology, Kerdang Kerbau Women's and Children's Hospital, Women's Tower Level 6, 100 Bukit Timah Road, Singapore 229899, Singapore.

E-mail address: [yongkuei@hotmail.com](mailto:yongkuei@hotmail.com) (T.Y.K. Lim).

<http://dx.doi.org/10.1016/j.gmit.2014.02.006>

2213-3070/Copyright © 2014, The Asia-Pacific Association for Gynecologic Endoscopy and Minimally Invasive Therapy. Published by Elsevier Taiwan LLC. All rights reserved.

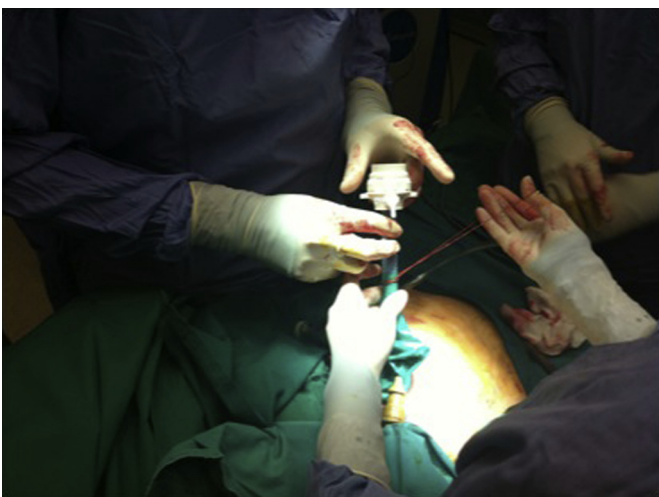


**Fig. 1.** The Alexis wound retractor is inserted into the peritoneal cavity after making the umbilical incision. The surgical glove is then applied over the outer ring of the Alexis wound retractor in our self-constructed single-port system.

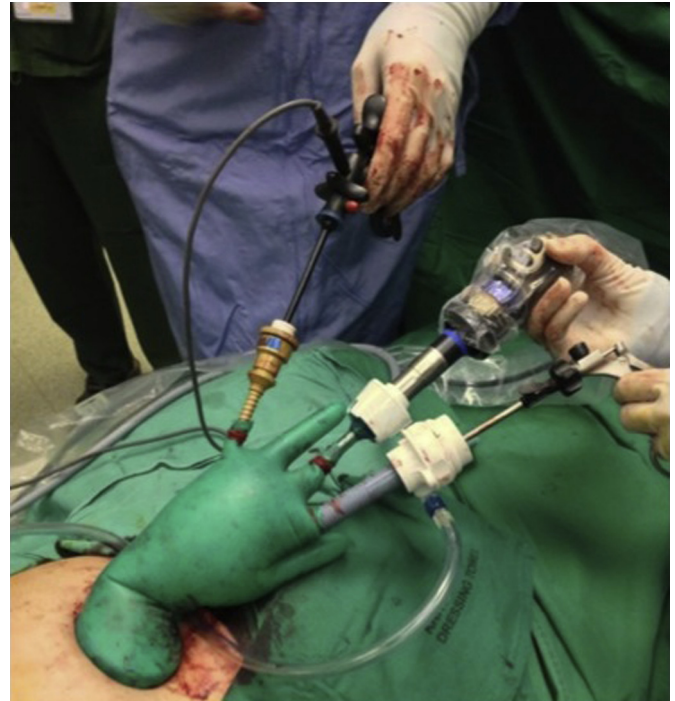
The patient was discharged on the 5<sup>th</sup> postoperative day after an uneventful recovery. She returned for outpatient follow up 3 weeks later and the surgical wound had healed well. The final histological results revealed that both tubes and ovaries, as well as all 26 pelvic lymph nodes, were negative for malignancy. She was confirmed to have a FIGO Stage IA Grade 1 endometrial cancer.

#### Surgical technique

We used a self-constructed single-port system (Figs. 1–3) based on the Korean model<sup>8,9</sup> using an Alexis wound retractor and non-powdered size 7.5 surgical glove. The peritoneal cavity was entered through a 2 cm vertical intra-umbilical skin incision and the Alexis (XS) wound retractor was inserted into the peritoneal cavity through the umbilicus. Small incisions were made to the fingertip portions of the surgical glove through which the ports are placed. The surgical glove is held in place by the rigid outer ring of the Alexis wound retractor (Applied Medical, Rancho Santa Margarita, CA, USA). A 5–12 mm Versaport (Covidien (Mansfield, MA, USA)) disposable trocar was inserted into one of the small



**Fig. 2.** A disposable 10 mm trocar is inserted into one of the small incisions made in the fingertips of the glove and is then secured with a rubber band.



**Fig. 3.** Our single-port system after gas insufflation and insertion of the 10 mm endoscope and an additional 5 mm plastic trocar. All trocars were secured in the fingertips of the glove with rubber bands.

incisions on one fingertip of the glove and secured with a rubber band. A rigid 5 mm endoscope was placed through another incision and another 5 mm trocar was included in the same manner. We used a combination of the Harmonic ACE and conventional bipolar electrocautery to perform the surgery.

The lymph nodes were removed systematically through the Versaport and the ovaries and tubes were removed through the Alexis retractor at the end of the operation. This prevented any potential contamination of the umbilical subcutaneous tissue. The estimated blood loss at the end of the operation was 100 mL.

#### Discussion

LESS is a relatively new technique. It has been reported to be a safe and feasible technique in patients with benign gynecological disorders.<sup>1–3</sup> The currently available reports<sup>1–3,10</sup> on gynecological LESS procedures suggests at least equivalent, if not better, outcome measures (complications, operative times, estimated blood loss, length of hospital stay, and cosmesis) compared with conventional multiport laparoscopy. In theory, operative complications related to insertion of the trocar, such as vessel and organ injuries, may be reduced as there are fewer inserted trocars. The safety and feasibility of this technique in patients with gynecological malignancies have also been demonstrated.<sup>4–8</sup> The use of LESS techniques for lymph node dissection in patients with gynecological malignancies is less well reported.<sup>5–8</sup> In a multicenter retrospective study of 100 patients by Fagotti et al,<sup>4</sup> the patients responded positively with respect to the cosmetic result and had minimal requirements for postoperative pain control. Both the median (range) operative time [129 (45–321) minutes] and estimated blood loss [70 (10–500) mL] were greater when staging lymphadenectomy was performed. The median (range) number of pelvic and para-aortic lymph nodes [16 (1–33) and 7 (2–28), respectively] retrieved in this LESS series were similar to the results for multiport laparoscopy or laparotomy.<sup>10</sup> In our patient, 26 pelvic lymph nodes were retrieved. Our

operative time was 188 minutes and the intraoperative blood loss was 100 mL, comparable with the results in the multicenter series.

The main limitation of LESS is its poor ergonomics. Collisions between instruments or between instruments and the endoscope, as well as the limited mobility of conventional straight laparoscopic instruments, limit the number of instruments which can be used through a single port. The camera platform may also be less stable as multiple instruments share the same single incision. These technical difficulties may reduce the accuracy of the operation and may result in a longer operation time. Angled instruments, which have been introduced to address these problems, tend to be costly and are therefore not used widely. In two separate papers by Korean surgeons,<sup>8,9</sup> on which we based our single-port model, the techniques involved using a home-made single-port system with a wound retractor and surgical gloves, as well as conventional laparoscopic instruments, to reduce costs.

In this first attempt to use a modified self-constructed single-port system, the main problems we encountered were as follows. First, there were collisions between the camera and the surgical instruments. As we were using conventional straight laparoscopic instruments through a single incision, clashes between the camera and the instruments required frequent adjustment of the operating angles. Second, we had a poor view with a standard 5 mm rigid endoscope. An upgrade to a high-definition 5 mm endoscope system may help with this. The camera platform was unstable and using a commercial single-port system may help, although this would increase the costs. Third, we had only a limited number of surgical instruments. In some circumstances, additional instruments are required to grasp tissue or for traction, coagulation for hemostasis, or for the dissection of pelvic adhesions. By using the fingertips of the surgical glove we were able to simultaneously insert two conventional instruments, one instrument into each separate fingertip, in addition to a 10 mm endoscope. However, we acknowledge that it may be technically difficult to operate if a third instrument is inserted. Finally, we took 188 minutes to perform the operation, which was longer than the time required to perform the same procedure using conventional four-port laparoscopy (approximately 60–90 minutes for bilateral PLND and salpingo-oophorectomy). This was partly due to the fact that we had to spend 1 hour performing adhesiolysis and salpingo-oophorectomy prior to the pelvic lymphadenectomy.

We believe that we will be able to overcome these technical difficulties with more practice. In addition, with further modifications to our single-port system and proper patient selection, operative times could be reduced. In a pilot study of 20 LESS hysterectomy procedures for early endometrial cancers,<sup>5</sup> there was a rapid decrease in operative time after ten procedures, showing a statistically significant improvement in the learning curve.

Single-port laparoscopy may eventually be offered to a select group of patients in place of conventional multiport laparoscopy in the management of early endometrial cancers. We conclude that single-port laparoscopic PLND appears to be a feasible option for a select group of patients requiring surgical re-staging of endometrial cancers.

## References

1. Nickles FA, Rogas-Espallat L, Ibeanu O, Grumbine FC, Escobar PF. Laparoendoscopic single-site surgery (LESS) in gynecology: a multi-institutional evaluation. *Am J Obstet Gynecol.* 2010;203:e1–e6.
2. Behnia-Willison F, Foroughinia L, Sina M, McChesney P. Single incision laparoscopic surgery (SILS) in gynaecology: feasibility and operative outcomes. *Aust N Z J Obstet Gynaecol.* 2012;52:366–370.
3. Park JY, Kim TJ, Kang HJ, et al. Laparoendoscopic single site (LESS) surgery in benign gynecology: perioperative and late complications of 515 cases. *Eur J Obstet Gynaecol Reprod Biol.* 2011;154:81–84.
4. Fagotti A, Boruta II DM, Scambia G, Fanfani F, Paglia A, Escobar PF. First 100 early endometrial cancer cases treated with laparoendoscopic single-site surgery: a multicentric retrospective study. *Am J Obstet Gynecol.* 2012;6:353.e1–353.e6.
5. Fanfani F, Rossito C, Gagliardi ML, et al. Total laparoendoscopic single-site surgery (LESS) hysterectomy in low-risk early endometrial cancer: a pilot study. *Surg Endosc.* 2012;26:41–46.
6. Boruta DM, Growdon WB, Schorge JO. Single incision laparoscopic staging for endometrial cancer. *J Am Coll Surg.* 2011;212:e1–e5.
7. Escobar PF, Fader AN, Rasool N, Espallat LR. Single-port laparoscopic pelvic and para-aortic lymph node sampling or lymphadenectomy: development of a technique and instrumentation. *Int J Gynecol Cancer.* 2010;20:1268–1273.
8. Hahn HS, Kim YW. Single-port laparoscopic pelvic lymph node dissection with modified radical vaginal hysterectomy in cervical cancer. *Int J Gynecol Cancer.* 2010;20:1429–1432.
9. Paek J, Kim SW. In: Darwish A, ed. *Single-port Access Laparoscopic Surgery in Gynecology: Technical Tips, Advanced Gynecologic Endoscopy*; 2011. <http://dx.doi.org/10.5772/17624>. Available from: <http://www.intechopen.com/books/advanced-gynecologic-endoscopy/single-port-access-laparoscopic-surgery-in-gynecology-technical-tips>.
10. Boggess JF, Gehrig PA, Cantrell L, et al. A comparative study of 3 surgical methods for hysterectomy with staging for endometrial cancer: robotic assistance, laparoscopy, laparotomy. *Am J Obstet Gynecol.* 2008;199:360.e1–360.e9.