



Short communication

Surgical management of cesarean scar pregnancies – A single tertiary experience

Xiaohui Ong^{a,*}, Manisha Mathur^a, Cynthia Kew^b, Bernard Chern^{a,b}^a Department of Obstetrics and Gynaecology, KK Women's and Children's Hospital, 100 Bukit Timah Road, Singapore 229899^b Department of Minimally Invasive Surgery, KK Women's and Children's Hospital, 100 Bukit Timah Road, Singapore 229899

ARTICLE INFO

Article history:

Received 25 November 2013

Received in revised form

3 May 2014

Accepted 7 May 2014

Available online 9 July 2014

Keywords:

cesarean scar pregnancy

complications

fertility

hemorrhage

uterine rupture

ABSTRACT

Cesarean scar pregnancies (CSPs) are a rare complication of previous cesarean deliveries. As cesarean section rates continue to increase worldwide, the incidence of CSPs is likely to rise as well. The diagnosis and management of CSPs pose challenging problems to clinicians. Early accurate diagnosis is crucial, as CSP is a life-threatening emergency that can lead to potentially catastrophic consequences such as uterine rupture, hemorrhage, loss of fertility and maternal death. There is no general consensus, however, regarding the best means of management. Various case reports and case series have reported successful outcomes with medical treatment, surgical intervention, interventional radiology, as well as a combination of methods. We present a case series of CSPs managed in our center, a tertiary obstetrics and gynecology hospital. All were treated primarily by conservative and fertility-sparing surgical methods. We have also included a short review of the current literature on this rare but important condition.

Copyright © 2014, The Asia-Pacific Association for Gynecologic Endoscopy and Minimally Invasive Therapy. Published by Elsevier Taiwan LLC. All rights reserved.

Introduction

Implantation of an ectopic pregnancy within a previous cesarean section scar is a rare phenomenon. The exact incidence of cesarean scar pregnancies (CSPs) is reported to be 1 in 1,800–2,216 pregnancies^{1,2} but is most likely increasing due to the increased number of cesarean sections (CSs) being performed. In our center, we deliver more than 12,000 babies a year, of which up to 30% are delivered by cesarean section.

Current literature does not seem to show any general consensus for the treatment of CSPs.^{1–11} The only conclusion based on case reports and case series suggests that there is little or no role for a conservative “do-nothing” approach to CSPs.⁴ Early diagnosis and treatment are important to prevent the possibly catastrophic consequences that may result from this rare but significant late complication of cesarean section. These include, but are not limited to, uterine rupture and/or hysterectomy, with significant morbidity resulting from loss of fertility, disseminated intravascular coagulation, and also maternal mortality.^{3,5}

KK Women's and Children's Hospital in Singapore is a tertiary obstetrics and gynecology hospital that performs more than 1,500 laparoscopic operations each year. We have a dedicated “minimally invasive surgery” department with senior staff trained in level 3 laparoscopic and hysteroscopic procedures. The primary aim of our study is to present our surgical experience in the management of CSPs, mainly by laparoscopy, hysteroscopy, suction curettage, and a combination of these methods, in our center within a specified period. Our secondary aim is to review the current literature available for optimal management of CSPs.

Materials and methods

We conducted a retrospective review of the CSPs diagnosed and treated surgically in our center during the period of May 2012 to June 2013. All cases were diagnosed on transvaginal ultrasound by a senior radiologist and confirmed intraoperatively. They were all co-managed by the primary gynecology team and a specialist gynecologist in our hospital's minimally invasive surgery unit. Conservative surgical methods – either laparoscopy or hysteroscopy, suction curettage under ultrasound guidance, or a combination of these methods, without requiring laparotomy or hysterectomy – were employed in the management of all our patients.

Conflicts of interest: The authors declare no conflicts of interest.

* Corresponding author. KK Women's and Children's Hospital, 100 Bukit Timah Road, Singapore 229899.

E-mail address: ong.xiaohui@kkh.com.sg (X. Ong).

<http://dx.doi.org/10.1016/j.jgmit.2014.05.009>

2213-3070/Copyright © 2014, The Asia-Pacific Association for Gynecologic Endoscopy and Minimally Invasive Therapy. Published by Elsevier Taiwan LLC. All rights reserved.

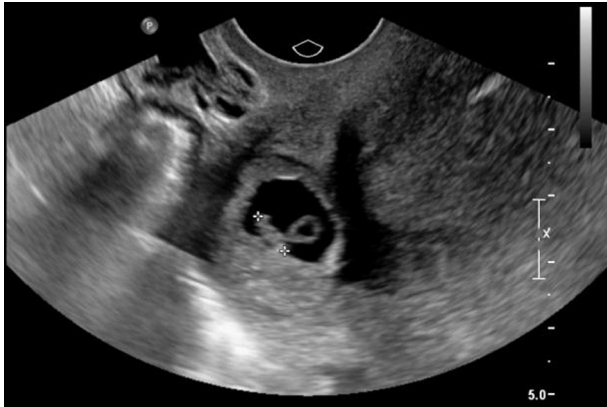

Fig. 1. Case 2. Repeated transvaginal scan 3 days after initial presentation (as the patient declined treatment initially) shows a gestational sac with yolk sac and fetal pole at the site of the previous uterine scar.

Data were collected in specially designed datasheets that included information pertaining to age, parity, symptoms at first presentation, previous uterine surgery or cesarean section, seniority of the surgeon performing previous cesarean section, maternal serum *human chorionic gonadotropin* (hCG) levels, and features of scan findings along with follow up details (Figs. 1–5).

A literature search was also performed to look at similar case studies and case series reviews that discussed methods of management of CSPs, particularly surgical methods.

Results and case summaries

Clinical details of the patients are summarized in Table 1. Serum hCG levels are expressed in IU/L. Cases 2 and 4, which had a more complicated course of treatment, are described in more detail.

Case 2

A 30-year-old Chinese woman G3P1 (1 previous 1st trimester abortion and 1 previous Cesarean section for failure to progress 13 months earlier) presented at 5 weeks' amenorrhea having had vaginal spotting for 1 week. She developed mild abdominal pain. She was referred from her private obstetrician, who noted no intrauterine gestational sac despite β hCG levels rising from 1,574 IU/L to 4,357 IU/L in 48 hours. Clinical examination was unremarkable. A transvaginal scan showed a 6 mm \times 5 mm \times 5 mm scar ectopic pregnancy.

She was offered intramuscular methotrexate but the patient initially declined treatment and wanted to seek a second opinion at another center. She returned 3 days later. She was asymptomatic. A transvaginal scan was repeated, which revealed a larger sac in the same area measuring 16 mm \times 7 mm \times 5 mm (Fig. 1). A yolk sac and fetal pole were now visualized. No cardiac activity was noted. Maternal serum β hCG had risen to 31,153 IU/L. She was re-offered systemic methotrexate and informed of the possibility of failure of medical therapy and need for either a repeat dose of methotrexate or surgical intervention. The option of laparoscopic-guided suction curettage with possible excision of the ectopic pregnancy and uterine suturing was discussed with the patient. She was given methotrexate initially, but eventually underwent laparoscopic-guided suction curettage and excision of the CSP 2 days later (Fig. 2).

Intraoperative findings were that of an 8-week sized uterus that was very anteverted and plastered to the anterior abdominal wall along the lower and mid segment. Both tubes and ovaries appeared normal. There was a small amount of hemoperitoneum, estimated to be 50 mL. There was an area of deficiency, 3 cm \times 2 cm, noted at the anterior lower segment with products of conception (POC) seen protruding out of the previous cesarean scar. Adhesiolysis was performed to free up the anterior wall of the uterus. POC were then removed from the area of perforation over the previous cesarean

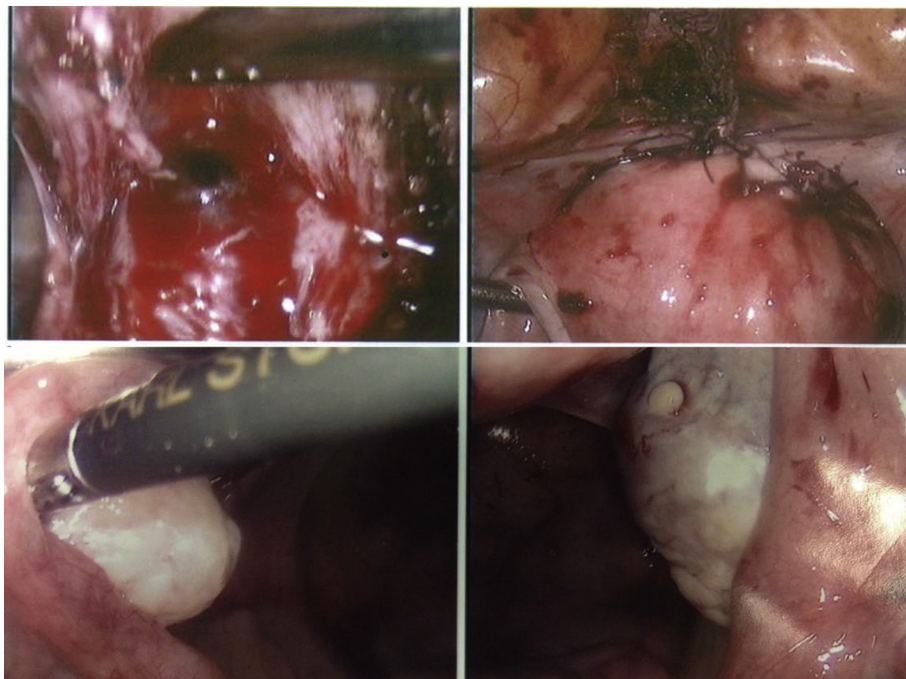


Fig. 2. Case 2. Laparoscopic images showing excision of the cesarean scar pregnancy and the sutured defect on the anterior uterine wall. Interrupted Vicryl-0 sutures were used for closure of the defect. Bilateral tubes and ovaries appeared normal.

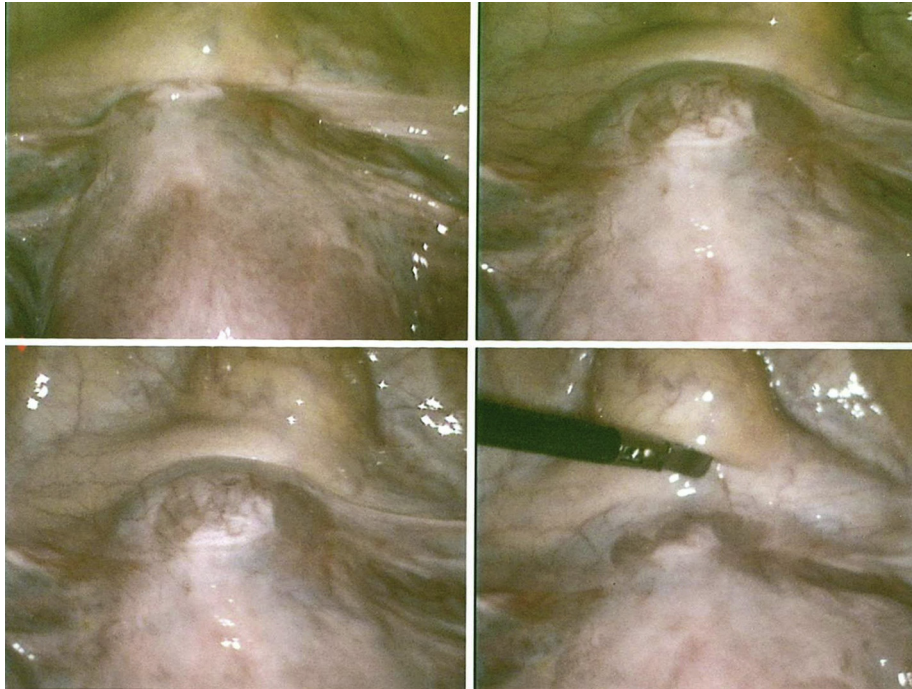


Fig. 3. Case 3. Diagnostic laparoscopy showing the cesarean scar pregnancy. Suction curettage under direct laparoscopic guidance was performed successfully. No therapeutic laparoscopy was required.

scar. The uterine defect was sutured in multiple layers with Vicryl 2–0 and 0. Hysteroscopy confirmed the presence of POC in the endometrial cavity as well. Suction curettage was performed under laparoscopic guidance.

The patient made an uneventful recovery, β hCG levels dropped to 16,993 IU/L on postoperative Day 1, and she was discharged on postoperative Day 2. She was seen 2 weeks later and repeated β hCG was 1,262 IU/L. Her β hCG continued to fall to 194 IU/L 1 week later. Repeat urine pregnancy test after a further 2 weeks was negative and she had resumed menstruation in the same week. She was extensively counseled with regards to the risk of recurrence of CSP, uterine rupture, and dehiscence and placenta accreta for future pregnancies. Contraceptive advice was also given.

Case 4

A 34-year-old Indian woman G3P2 with two previous Cesarean sections presented at 7 weeks of amenorrhea, with *per vaginam* staining. She did not have any abdominal pain or giddiness. She had taken two courses of mifepristone and misoprostol 9 days and 3 days previously, respectively. There were no prior scans carried out prior to when she was given the prescriptions by a private doctor. She was not on any contraception.

Transvaginal scan showed an empty uterus, with endometrial thickness at 8.2 mm. There was a gestational sac seen at the site of the previous uterine scar, with a fetal pole of 8.5 mm at about 7 weeks' gestation with fetal cardiac activity present. The overlying

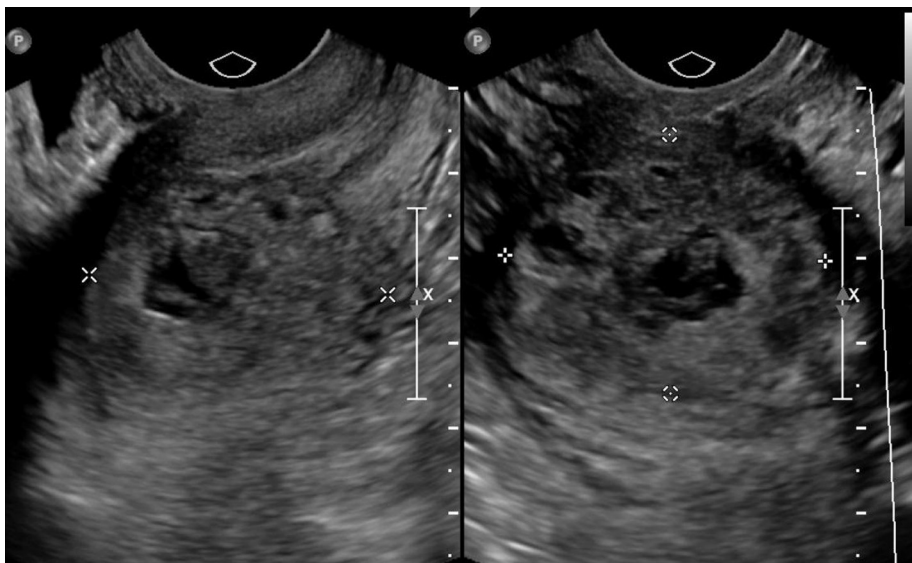


Fig. 4. Case 4. A heterogeneous mass was seen after the resolution of the gestational sac and fetal pole, increasing in size 2–3 weeks after initial treatment with intra-sac methotrexate injection.

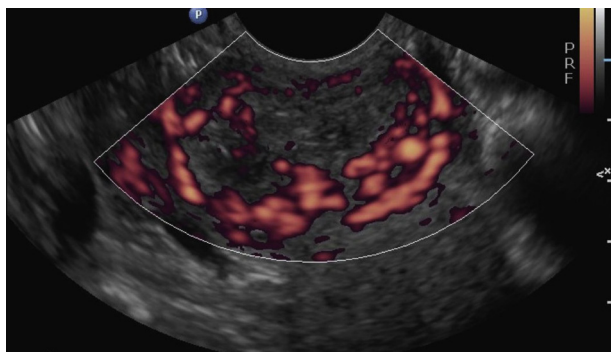


Fig. 5. Case 4. Color Doppler showing increased hypervascularity of the heterogeneous mass in the region of the scar ectopic pregnancy. The patient subsequently underwent hysteroscopic and laparoscopic-guided suction curettage as secondary treatment.

myometrium measured about 4.2 mm. No free fluid was seen. The impression was that of a live unruptured scar ectopic pregnancy. Serum β hCG level was 86,116 IU/L. Hemoglobin level was 9.9 g/dL. She remained clinically stable.

The management options were discussed with the patient. Surgical hysteroscopic and laparoscopic removal of the sac, evacuation, and resection of the scar ectopic pregnancy, as well as medical management with intra-sac or intramuscular methotrexate were offered. She was counseled extensively about the risks and benefits of each treatment option. She decided on ultrasound-guided intra-sac methotrexate and inpatient monitoring.

Ultrasound-guided intra-sac methotrexate injection of 50 mg was performed the next day. Post-procedural fetal cardiac activity was absent. Repeat β hCG the next day was 100,153 IU/L. She remained hemodynamically stable and asymptomatic and she was therefore discharged.

Repeat β hCG 5 days post methotrexate was 101,500 IU/L. Her hemoglobin remained stable at 9.6 g/dL. Transvaginal scan showed a fetal pole measuring 3.1 cm \times 2.2 cm \times 2.0 cm and a cystic area containing low-level internal echoes and some loculations. Endometrial thickness was 4 mm. One week later, β hCG further decreased to 223,614 IU/L. Transvaginal scan was not repeated at this visit.

Two weeks later at follow-up, the patient's β hCG was 584 IU/L. She was asymptomatic. Transvaginal scan showed a heterogeneous mass with increased peripheral hypervascularity seen in the region of the lower endometrial/endocervical canal, measuring 3.8 cm \times 3.5 cm \times 3.0 cm, with internal echoes and loculations (Fig. 4). This was larger in size than at the previous scan. A trace amount of free fluid was seen. She was reoffered surgery in view of the risk of rupture and hemoperitoneum due to the increase in size of the scar ectopic. She opted for conservative management and was given another outpatient appointment in 4 days' time.

She returned for follow up as planned, and was still asymptomatic. Her repeat β hCG measurement was 302 IU/L. Transvaginal scan showed that the same mass had increased in size to 4.0 cm \times 3.7 cm \times 3.0 cm (Fig. 5). There was no free fluid in the pelvis. She was offered surgery again in view of the scar's increasing size and higher risk of rupture. She requested tubal sterilization at the same time.

Intraoperative findings were that of a uterus with dense adhesions from the anterior wall and fundus to the anterior abdominal wall. Both tubes and right ovary were normal but there was a small left paraovarian cyst. Hysteroscopy showed products of conception around the isthmus. Laparoscopic adhesiolysis was carried out. Suction curettage was performed under direct laparoscopic guidance, with a hysteroscopy check post procedure. Her bilateral tubes

were sterilized using Filsch Clips (CooperSurgical Inc., Trumbull, CA, USA).

She was well postoperatively, and her β hCG levels dropped to 117.9 IU/L on postoperative Day 1. She was discharged on postoperative Day 2 and was reviewed 2 weeks post operation. She remained clinically well. Histology confirmed products of conception and a β hCG level of 3.9 IU/L. Transvaginal scan was normal. At further follow up 2 weeks later, her β hCG was <1.2 IU/L and her transvaginal scan remained normal.

Discussion

The cause and pathophysiology of CSPs is not well understood. As described in a review article by Ash et al,⁴ in a cesarean scar ectopic pregnancy, the gestation sac is completely surrounded by myometrium and the fibrous tissue of the scar, and is separate from the endometrial cavity. The most probable mechanism is invasion of the myometrium through a microtubular tract between the cesarean section scar and the endometrial canal. Predisposing factors therefore include previous surgery and instrumentation of the uterus, which may cause such a microtubular tract. In our series, three out of four women had undergone previous uterine instrumentation. It is uncertain whether the risk of CSP is related to the number of previous cesarean sections. In our series, two women had two previous CSs, whereas the other two women had one previous cesarean section.

As we had only five cases in this series, we were unable to draw any conclusions on the postulated predisposing factors of CSPs. There has been little literature on this. Some review articles have reported conflicting data as to whether the number of previous lower segment CS is a strong risk factor for CSP. There are also limited data^{4–6} on any correlation between the CSP and the indication of the previous CS, whether surgical technique of uterine closure at previous CS may cause CSP, or if the time interval between the previous lower segment CS and CSP plays a contributory role.

In our series, all five women were symptomatic with bleeding *per vaginam*; three women had associated cramps. In a review of 57 cases by Rotas et al,³ 38.6% of patients presented with painless vaginal bleeding, and only 24.6% had abdominal pain. Of the 57 women, 36.8% were asymptomatic. In our series, all of the women were diagnosed early at first presentation, in the first trimester. It is important to highlight that these patients were initially seen at our early pregnancy care unit and scanned by gynecologists, followed by confirmatory scans by trained sonographers and radiologists. Increased awareness, high suspicion of CSPs, as well as good sonographic skills probably contributed to early accurate diagnosis of CSPs in our center.

Published articles to date^{1–9} suggest that transvaginal ultrasound, aided by color flow Doppler, provide a high diagnostic accuracy with few false positives. Diagnoses of all five women were established by transvaginal ultrasound at presentation, early in the first trimester. Ultrasonic features fitted the criteria as described in the review article by Ash et al.⁴ These included an empty uterine cavity, without contact with the sac; a clearly visible empty cervical canal, without contact with the sac; the presence of the gestation sac with or without a fetal pole with or without fetal cardiac activity in the anterior part of the uterine isthmus; and the absence of or a defect in the myometrial tissue between the bladder and the sac (see Fig. 1).

Our five patients were treated with conservative surgery, despite efforts to treat three cases with methotrexate initially. They were all clinically stable at the point of diagnosis and treatment. None of them required laparotomy or hysterectomy. One woman was managed by ultrasound-guided suction curettage as the scar

Table 1
Clinical data of women with uterine scar pregnancies.

Case	Age	Parity	Number of weeks of amenorrhea	Presentation	Previous operation	Scan features	β-hCG (IU/L)	Progress and outcome	Follow-up
1	30	G2P1	5	Vaginal spotting	1 CS, 1 D+C	0.8 cm × 0.7 cm × 0.8 cm cystic structure with thin surrounding echogenic rim noted at the lower endometrial cavity which extends into the adjacent lower segment CS scar. No yolk sac or fetal pole.	2,011 → 5,824 (at 48 h) → 22,380 at second treatment	Failed systemic intramuscular methotrexate, followed by suction curettage under laparoscopic guidance 3 d later.	4 wk: βhCG 6.4; 5 wk: scan normal
2	30	G3P1	5	Vaginal spotting and mild abdominal pain	1 CS, 1 TOP	First presentation: anechoic area 0.6 cm × 0.5 cm × 0.5 cm with echogenic rim at the lower segment uterine scar. No definite yolk sac or fetal pole. Went to seek second opinion and returned 3 d later. Showed 1.6 cm × 0.7 cm × 0.5 cm sac in the cesarean scar area. Yolk sac and fetal pole seen but no fetal cardiac activity. Endometrial thickness heterogeneous and measured 1.2 cm.	1,574 → 4,357 (at 48 h) Went to seek second opinion. Another 72 h later 31,153.	Systemic intramuscular methotrexate, followed by semi-elective laparoscopic adhesiolysis and repair of the scar ectopic defect at the lower segment and suction curettage under laparoscopic guidance 2 d later.	2 wk: serum βhCG dropped to 195. 4 wk: urine βhCG negative.
3	25	G4P2	6	Vaginal spotting and intermittent pain. Unplanned pregnancy on oral contraception	2 CS, 1 evacuation of uterus	Sac in cesarean scar of the lower anterior uterine wall. Yolk sac and fetal pole seen. CRL 0.7 cm corresponding to 6 wk, 6 d of gestation, with myometrium superficial to decidual reaction 2.3 mm in depth. Endometrial thickness: 23 mm	34,103	Suction curettage under laparoscopic guidance. (Serosa intact. Did not require therapeutic laparoscopy.)	2 wk: post op βhCG 150. Defaulted follow up.
4	34	G3P2	7	Vaginal staining. Unplanned pregnancy and previously took 2 courses of mifepristone and misoprostol for TOP.	2 CS	2.7 cm × 1.8 cm × 1.4 cm sac seen in lower segment of the uterus. CRL 8.5 mm corresponding to 7 wk of gestation with fetal cardiac activity. Overlying myometrium measured 4.2 mm. Transvaginal ultrasound 2 wk post methotrexate showed a heterogeneous mass with increased peripheral hypervascularity in the same region of the scar ectopic pregnancy, measuring 3.8 cm × 3.5 cm × 3.0 cm. Patient opted for conservative treatment. Four d later, transvaginal ultrasound showed increasing size of the same mass to 4.0 cm × 3.7 cm × 3.0 cm. No free fluid in pelvis.	86,116 post methotrexate: Day 1 100,153 → Day 5 101,500 Day 19 584	Failed response to ultrasound-guided intra-gestational sac methotrexate. Opted for conservative management initially. Suction curettage under hysteroscopic/laparoscopic guidance about 3 wk after methotrexate. Tubal sterilization was also performed at patient's request.	6 wk: βhCG 3.9, transvaginal ultrasound was normal. 8 wk: βhCG <1.2
5	21	G3P2	5	Vaginal spotting and right iliac fossa pain	2 CS	3.4 cm × 1.2 cm × 0.9 cm gestational sac in the mid endometrial cavity, extending towards the previous CS scar area. The myometrium over the gestational sac appeared thinned out. Small yolk sac and fetal pole are seen within the gestational sac.	35608 → 12321 (POD1) → 330 (POD7)	Ultrasound guided suction curettage	3 wk: hCG undetectable

CS = cesarean section; CRL = crown-rump length; TOP = termination of pregnancy.

ectopic was growing towards the uterine cavity. In all cases, maternal recovery was uneventful. None required blood transfusion.

In a previous review from our center,¹⁰ two cases required laparotomy due either to delayed presentation or delayed diagnosis. One woman who presented late, at 16 weeks, required a subtotal hysterectomy due to massive hemorrhage. Early recognition and active management of CSPs seems to have eliminated the need for laparotomy and hysterectomy during the management of these cases in the past year. This may be explained by increased awareness of the condition and the increasing use of ultrasound in early pregnancy.

Expectant management seems to have little or no role in the management of CSPs already diagnosed on ultrasound.⁴ Sadeghi et al⁶ reviewed 268 cases from various case reports and series that showed that out of 21 cases which were managed expectantly, 14 women (67%) required subsequent intervention, and six of these cases (29%) ultimately required hysterectomy. Studies have not shown a consistent threshold of maternal serum hCG levels or ultrasonic features that warrant a decision to choose surgical treatment over medical treatment.^{4–6} Furthermore, response to medical treatment is often unpredictable.^{5,6} Most studies agree that continuation of fetal cardiac activity or growth of the sac with rising serum hCG levels indicate failure of medical treatment.

Blind curettage as a primary treatment for CSP is not recommended by some authors.^{4,8} A number of authors, however, do choose to perform suction curettage under ultrasound guidance. In theory, the lack of direct visualization of the CSP increases the risk of a local hematoma formation or uterine scar rupture, leading to severe hemorrhage. In a review article of 751 CSPs, Timor-Tristsh et al⁹ concluded that dilatation and curettage should be avoided if possible as it can lead to profuse bleeding, additional secondary backup procedures, general anesthesia, blood transfusion, and in many instances laparotomy and loss of the uterus. It is not clear whether this paper was specifically referring to blind dilatation and curettage. We agree that blind dilatation and curettage should not be used; however, our cases illustrated here all eventually underwent suction curettage, either as a part of a primary or secondary treatment modality. It is important to highlight that the surgeries were all performed under laparoscopic guidance, with or without hysteroscopic guidance.

As Ash et al⁴ stated in their review article, an experienced endoscopist should make the choice between a laparoscopy and hysteroscopy; an operative hysteroscopic approach should be chosen for the CSP that grows inwards toward the uterine cavity, whereas a laparoscopy is more justified for a deeply implanted CSP growing towards the abdominal cavity and bladder. Several reports^{4–6} have shown that laparoscopic excision is safe, with limited blood loss, and is associated with fast recovery. Similarly, hysteroscopy has a short operative time⁴ and direct visualization allows for safe removal of the products of conception. A recent case report by Chou et al⁷ has shown that hysteroscopic removal of CSP can be a safe option, not only for the initial treatment but also as rescue management after a failed methotrexate treatment attempt. The main advantage of these surgical methods is that fertility is conserved; however, in the event of severe hemorrhage or hemodynamic instability, conversion to laparotomy must be considered.

Current literature^{1–11} shows a wide extent of treatment modalities of CSPs, including ultrasound-guided methotrexate and potassium chloride intra-lesional injections, systemic intramuscular methotrexate injections, hysteroscopic, laparoscopic and laparotomy techniques, dilatation and curettage, uterine artery embolization, as well as varied combinations of the above

techniques. Uterine artery embolization as a primary treatment should be used sparingly and only for selected cases. Transvaginal or transabdominal ultrasound-directed methotrexate injection, with or without additional intramuscular methotrexate, with surgical excision by hysteroscopic guidance seemed to carry the lowest complication rate. There does not, however, appear to be consensus on choosing which mode of therapy for the management of CSP; this is highly center-dependent and based on individual experience.

In a retrospective case series⁹ of 26 patients in a single center, 19 were successfully treated with combined intramuscular and intra-gestational methotrexate injection. Two declined methotrexate and subsequently underwent hysterectomy for ruptured CSPs. In another earlier study by Timor-Tristsh and Monteagudo,⁸ the authors suggested that systemic methotrexate as a single treatment of choice should be avoided, due to its slow action and as it may require a delayed subsequent second-line treatment approach with higher complication rate. However systemic methotrexate appears to be more effective in women with hCG level <5,000 IU/L.² The success rate of systemic methotrexate treatment is 71–80%.^{4,6} For levels exceeding this, intra-lesional injection and/or other additional interventions are indicated.

Follow up of the patients post treatment included clinical assessment and monitoring of serum hCG levels for all five patients. The hCG levels were undetectable within 3–6 weeks postoperatively. A transvaginal scan was performed for Case 1, who was treated with intramuscular methotrexate only, and Case 4, who initially had an increasing size of ectopic gestation despite decreasing hCG levels after intra-sac methotrexate. This was in line with the recommendations by Sadeghi et al.⁶ Our patients all recovered uneventfully. Serum hCG levels were measured on postoperative Day 1, and repeated 1 week later. Subsequent hCG were repeated 1–2 weekly until levels became undetectable, except for one patient who did not attend her appointment.

Unfortunately due to the recent time frame of our case studies, we were unable to look into long-term and future fertility outcomes post-surgery for CSPs. In Sadeghi's literature review in 2010,⁶ follow-up data from 73 women conservatively treated for CSPs revealed 59 subsequent pregnancies, with an overall CSP recurrence rate of 20.5% (15 pregnancies). Of the remaining 44 pregnancies, 15 ended in elective or spontaneous abortion and one resulted in uterine rupture causing maternal and fetal mortality. In another paper by Maymon et al,¹¹ after cesarean scar pregnancy treatment, seven out of 18 women conceived spontaneously, one conceived following *in vitro* fertilization-intracytoplasmic sperm injection. The remaining 10 (55%) did not wish to conceive again. Two (25%) of the women who became pregnant had recurrent CSP. In another series of 15 CSPs by Seow et al,¹² there were seven subsequent conceptions with two sets of *in vitro* fertilization twin pregnancies. There was one recurrent CSP, and complications reported included one hysterectomy, one uterine rupture with maternal and fetal death, and one placenta accreta.

Limitations

We were limited by the lack of a proper database to capture all the scar ectopic pregnancies that have been managed in our center. There was also a lack of a specific coding system for cesarean scar ectopic pregnancy. Hence we could only include the cases that have been managed over the past year. Also, due to the small numbers and the fact that the patients were all managed by different primary surgeons, there was no standardization of treatment and follow up protocols.

Current data with regards to long-term fertility outcomes for women with previously-treated CSPs are still limited. It would be interesting to follow up on these patients to look into the pregnancy outcomes of women who have had conservative surgery for CSPs. We would also like to suggest setting up a coding system and database to record all CSPs in our unit for further follow-up and research purposes.

Conclusion

Currently, there is no recommended standard treatment of scar ectopic pregnancy. We do not advocate blind dilatation and curettage in the management of CSPs, but conclude that in experienced hands, conservative surgery is effective and safe in hemodynamically-stable patients. Early diagnosis and treatment likely allow success of conservative surgery, such as laparoscopic and hysteroscopic excision and guided suction curettage. These surgical methods appear to have good short-term outcomes and are associated with lower maternal morbidity than laparotomy and hysterectomy. They are also a good definitive treatment option for patients who decline methotrexate, or patients with potentially poor follow-up compliance.

There is little or no role for the conservative management of CSPs. In cases presenting with greater serum hCG levels and/or ultrasound findings of a gestational sac with fetal pole, and/or symptoms of pain, it may be prudent to consider surgery earlier rather than later to prevent catastrophic consequences.

References

1. Seow KM, Huang LW, Lin YH, Lawrence A, Salim R, Elson CJ. Cesarean scar pregnancy: issues in management. *Ultrasound Obstet Gynecol.* 2004;23:247–253.
2. Jurkovic D, Hillaby K, Woelfer B, Lawrence A, Salim R, Elson CJ. First-trimester diagnosis and management of pregnancies implanted into the lower uterine segment caesarean section scar. *Ultrasound Obstet Gynecol.* 2003;21:220–227.
3. Rotas MA, Haberman S, Levgur M. Cesarean scar ectopic pregnancies: etiology, diagnosis, and management. *Obstet Gynecol.* 2006;107:1373–1381.
4. Ash A, Smith A, Maxwell D. Cesarean scar ectopic pregnancy. *BJOG.* 2007;114:253–263.
5. Michener C, Dickinson JE. Cesarean scar ectopic pregnancy: a single centre case series. *ANZJOG.* 2009;49:451–455.
6. Sadeghi H, Rutherford T, Rackow BW, et al. Cesarean scar ectopic pregnancy: case series and review of the literature. *Am J Perinatol.* 2010;27:111–120.
7. Chou YM, Wu D, Wu KY, Lee CL. Hysteroscopic removal of cesarean scar pregnancy after methotrexate treatment failure. *Gynecol Minim Invasive Ther.* 2013;2:70–72.
8. Timor-Trisch IE, Monteagudo A. Unforeseen consequences of the increasing rate of cesarean deliveries: early placenta accreta and cesarean scar pregnancy. A review. *Am J Obstet Gynecol.* 2012;207:14–29.
9. Timor-Trisch IE, Monteagudo A, Santos R, Tsybal T, Pineda G, Arslan AA. The diagnosis, treatment, and follow-up of cesarean scar pregnancy. *Am J Obstet Gynecol.* 2012;207:44. e1–13.
10. Tagore S, Teo SH, Chua SY, Ong CL, Kwek YC. A retrospective review of uterine scar pregnancies: single centre experience. *Arch Gynecol Obstet.* 2010;282:711–715.
11. Maymon R, Svirsky R, Smorgick N, et al. Fertility performance and obstetric outcomes among women with previous cesarean scar pregnancy. *J Ultrasound Med.* 2011;30:1179–1184.
12. Seow KM, Hwang JL, Tsai YL, Huang LW, Lin YH, Hsieh BC. Subsequent pregnancy outcome after conservative treatment of a previous cesarean scar pregnancy. *Acta Obstet Gynecol Scand.* 2004;83:1167–1172.