



Review article

Approaches to adenomyomectomy



Serene Thain, Heng Hao Tan*

Reproductive Medicine Department, Reproductive Surgical Unit, KK Women's and Children's Hospital, Singapore

ARTICLE INFO

Article history:

Received 22 June 2013

Received in revised form

3 June 2014

Accepted 27 August 2014

Available online 2 April 2015

Keywords:

adenomyomectomy

adenomyosis

fertility-sparing surgery

ABSTRACT

Adenomyosis is a common gynecological condition that affects women, causing menstrual disturbances, pain, and subfertility. Adenomyomectomy as an alternative to hysterectomy has been widely performed in those who have not completed childbearing or those refusing a hysterectomy for a variety of reasons. Whichever the surgical route, the challenges of adenomyomectomy include possible misdiagnosis, defining the extent of resection, technical difficulties, dealing with the associated complications, and managing the risks of uterine rupture during a subsequent pregnancy. The principles of surgery mimic those of myomectomy, but the evolution of adenomyomectomy has been relatively unexciting with a general paucity of published data to date. Laparoscopic techniques have proven feasible generally, avoiding the risks of open surgery while conferring the benefits of microsurgery. Limitations in tactile feedback and access constraints have been the main drawbacks via this route. Meticulous stitching and repair is still of paramount importance in these operations. Preoperative gonadotropin-releasing hormone agonists have proven effective in shrinking the disease and reducing blood loss during surgery, whereas the postoperative use has resulted in a dramatic reduction in symptoms. Uterine artery ligation techniques have also been shown to be useful adjuncts, although we still need to be mindful of the potential effects in those desiring fertility. Furthermore, there is still no foolproof way in predicting those at risk of uterine rupture after adenomyomectomy. Hence, a nonprescriptive approach in managing adenomyomas is advised, where proper patient selection and counseling are important.

Copyright © 2015, The Asia-Pacific Association for Gynecologic Endoscopy and Minimally Invasive Therapy. Published by Elsevier Taiwan LLC. All rights reserved.

Introduction

Adenomyosis is a benign gynecological condition characterized by the presence of endometrial glands and stroma within the uterine musculature. It is usually diagnosed in multiparous women during the 5th decade of life¹ and is thought to affect 1% of the female population.² Women with adenomyosis can be asymptomatic or present with symptoms of menorrhagia, dysmenorrhea, and subfertility.

Adenomyosis can either be diffuse or focal, and the etiology and pathogenic mechanism of adenomyosis are poorly understood. Most studies favor the theory of endomyometrial invagination of the endometrium.³ Other theories include *de novo* development of adenomyosis from embryological misplaced pleuripotent Mullerian remnant, invagination of the basal layer proceeding along the

intramyometrial lymphatic system, or origination from bone marrow stem cells that are displaced through the vasculature.⁴

Hysterectomy remains the mainstay of treatment. However, conservative surgical management in the form of adenomyomectomy remains the recommended treatment for those who have not completed their childbearing.

The evolution of adenomyomectomy as a surgery has largely been “unexciting,” and there is a general paucity of data. Hyama⁵ introduced the first reported case of open adenomyomectomy in 1952. From 2000 onward, there was a move toward the concept of “radicalizing excision” and the introduction of laparoscopic techniques. In more recent years, evolution of endoscopy itself has resulted in first reported case of robot-assisted laparoscopic technique for adenomyomectomy.⁶

Challenges faced with adenomyomectomy

Diagnosis

Making an accurate diagnosis of adenomyoma is not straightforward, with it being frequently misdiagnosed as fibroids on

* Corresponding author. Reproductive Medicine Department, Reproductive Surgical Unit, KK Women's and Children's Hospital, 100 Bukit Timah Road, 229899 Singapore.

E-mail address: tan.heng.hao@kkh.com.sg (H.H. Tan).

ultrasound scan. Magnetic resonance imaging (MRI) is the most sensitive test for the detection of adenomyosis; however, it is also the most expensive, limiting access to affluent health care systems.⁷ This influences the way in which patients are counseled preoperatively and affects patients' outcomes achieved through surgery.

Extent of removal

Uncertainty in defining the site and extent owing to a lack of surgical plane makes it difficult to determine the extent of complete excision. One constantly needs to balance between inadequate removal of the adenomyoma versus excessive healthy myometrial excision that is detrimental to wound integrity.

Technical difficulties

The excision of ill-defined, tough adenomyotic tissue via laparoscopy is often difficult owing to a lack of tactile feedback. Robust suturing is also needed to close the defect while preventing the tearing of tissues. Techniques that have been recommended to enhance the strength of the sutures include the use of monofilament sutures, taking deep bites of the myometrium to prevent dead space formation and using interrupted sutures to reduce tension on the wound.

Associated complications

Potential complications of adenomyomectomy include intraoperative hemorrhage, postoperative formation of intra-abdominal adhesions that may cause pain or contribute to infertility, uterine rupture in future pregnancies, as well as recurrence of the pathology.

Pregnancy after adenomyomectomy

Preventing tubal damage is of paramount importance in patients desiring fertility. The uterine cavity should remain intact to allow for implantation. The uterine wall must be properly reconstructed to enable it to sustain fetal growth following conception, and adhesions should be minimized postoperatively as these may have an effect on fertility outcomes.

The removal of a significant amount of myometrium in adenomyomectomy leads to two problems. First, there is a reduction in myometrial capacity of the uterus during pregnancy. Second, the presence of a uterine scar may reduce tensile strength, thereby predisposing future pregnancies to an increased risk of uterine rupture.

Surgical techniques

The rationale for adenomyomectomy includes that of cytoreduction, debulking to relieve the mechanical disturbances, and correcting physiological disturbances that may impair sperm transport.

The established surgical principles of myomectomy are extended to adenomyomectomy with some key exceptions. For one, an anterior incision to minimize blood loss and keep the ovaries from adhering to the posterior wall of the uterus postoperatively may not always be possible. Also, the plane of an adenomyoma is often difficult to establish owing to the lack of clear demarcation between normal and diseased tissue, unlike that of a myoma.

Open technique

This is often regarded as the gold standard for the treatment of extensive disease, and is one that has been traditionally used. However, an open approach subjects the patient to risks and morbidity of open surgery, with it being less cosmetically appealing.

Laparoscopic technique

Laparoscopic gynecological surgery was developed to avoid laparotomy and its risks. It also allows for microsurgical principles to be applied, resulting in greater operative precision and reduction in trauma, adhesions, and bleeding.

Traditionally, laparoscopic adenomyomectomy is performed via wedge resection where the part of the seromuscular layer where the adenomyoma is located is removed. In this procedure, some of the adenomyotic tissue may remain on either side of the incision. Part of the muscle layer is then sutured, the tumor cavity is closed with absorbable sutures, and the residual seromuscular layer is sutured.

Surgical modifications to the traditional wedge resection have been developed to decrease complications and intraoperative blood loss, and the surgical techniques involved in laparoscopic modified adenomyomectomy are some of these modifications. The procedure of laparoscopic modified adenomyomectomy was described in a paper published in 2011 by Sun et al.⁸ Here, the uterine serosa is subjected to bipolar coagulation, and the uterine muscle is transversely cut by a unipolar incision of the adenomatous tissue. The adenomatous tissue is then resected until it is soft, at which time the assistant fixes the adenomatous tissue with grasping forceps. Hemostasis is achieved by use of electric coagulation. The "cave-like" wound is flushed, the tumor cavity is closed by U-shaped suturing of the muscle layer, and the seromuscular layer is closed by figure-of-eight sutures spaced at 1 cm.

The ongoing challenge with laparoscopy is how to excise enough diseased adenomyotic tissue laparoscopically while ensuring proper closure. A laparoscopic approach, associated with poorer operative access, does not allow for tactile feedback, thereby limiting the assessment of the extent of disease. This is aggravated by the presence of adhesions or an enlarged globular uterus. Therefore, technical constraints may be met when extensive excising and suturing is required.

The case series published by Morita et al.⁹ in 2004 included three women with focal adenomyosis that was excised laparoscopically. The lesions were preoperatively delineated with MRI, and all three patients involved received leuprolide acetate (1.88 mg) for 3–4 months preoperatively. There were no reported complications, and the average blood loss was 53.3 mL. The patients' symptoms disappeared by the first menstrual period after surgery. In this paper, the authors had highlighted that the most important point was to ensure precise diagnosis and evaluation of the adenomyosis preoperatively by MRI.

A radical excision technique was reported by Takeuchi et al.¹⁰ in 2006. Essentially, in this particular technique, a flap was created and sutured in an overlapping manner to fill in the dead space after excision. Fourteen women with symptomatic adenomyosis with a size of 30 mm or greater on MRI were included in the trial. Nine cases were administered gonadotropin-releasing hormone agonists (GnRH_a; leuprolide acetate), and one case was administered oral contraceptives. Postoperatively, the median visual analog scale score during menstruation significantly decreased ($p < 0.01$) from 10 (range, 9–10) prior to the operation to 2.5 (range, 1–6) after the operation. All eight cases of polyhypermenorrhea improved after the operation.

Subsequently, Grimbizis et al¹¹ reported on laparoscopic adenomyomectomy in 2008, where the authors concluded that laparoscopic management appears to be safe and feasible with good follow-up results and limited recurrence rates. Table 1 illustrates the papers that have been published since Morita et al's⁹ report was published in 2004. In essence, these results do validate that there is indeed a role for laparoscopy in modern-day treatment of adenomyomas.

Comparing open versus laparoscopic approach

Currently, there are no known published studies comparing outcomes between the open and laparoscopic approach to adenomyomectomy. However, robust evidence is available for myomectomy procedures. A systematic review published in 2009 comparing open versus laparoscopic myomectomy showed that laparoscopic myomectomy was associated with less hemoglobin drop, reduced operative blood loss, more patients fully recuperated at Day 15, diminished postoperative pain, and fewer overall complications but longer operation time with comparable major complications, pregnancy, and recurrence rates in both groups.¹² To examine if the same outcomes seen in myomectomies are applicable to adenomyomectomies, more studies need to be conducted looking specifically at adenomyomectomies.

Reducing adenomyomectomy risks during laparoscopy

This is primarily through a combination of surgical techniques and the utilization of adjuvants before or after the operation.

Hemorrhage

Preoperative GnRHa

There is a strong evidence for hormonal manipulation in the treatment of adenomyoma-related diseases.¹³

GnRHa have been used for the treatment of adenomyoma-related diseases, resulting in a reduction in uterine size and symptomatic improvement. However, this effect is often transient and most patients will experience a recurrence of their symptoms; therefore, there is a need for definitive treatment such as adenomyomectomy. This drug is primarily used preoperatively to decrease the size of the lesion, facilitate resection, and reduce intraoperative bleeding. Morita et al⁹ had documented an average of 53.3 mL of blood loss when GnRHa was used prior to resecting the adenomyomas. With reference to Table 1, this is perhaps one of the more effective ways to decrease blood loss.

Vasopressin

Vasopressin acts by constricting the smooth muscle in the walls of capillaries, small arterioles, and venules. Currently, there is no

available concrete evidence that the use of vasopressin reduces blood loss in adenomyomectomy procedures specifically. However, the role of vasopressin has been well established in myomectomies. Randomized trial data have shown that blood loss during myomectomy with vasopressin is significantly less than with placebo (299 mL less),¹⁴ and less than or comparable to use of a uterine artery tourniquet.^{15–17} Injecting vasopressin diluted in normal saline prior to making the incision on adenomyoma helps to decrease bleeding from the incision for about 20 minutes. However, it has been mentioned in the literature that possible drawbacks of the use of vasopressin in laparoscopic myomectomy include bleeding from the needle puncture sites, which often persists throughout the procedure, requiring later electrosurgical coagulation, and delayed bleeding in the myometrium.¹⁸ One needs to maintain vigilance in achieving hemostasis even when using vasopressin because of the risk of delayed bleeding, thereby rendering a false sense of security.

Oxytocin infusion

Oxytocin acts directly on the myometrium via its receptors on the uterine smooth muscle cells, stimulating contraction of the uterus and diminishing uterine perfusion. Oxytocin receptors also exist in the nonpregnant uterus,¹⁹ albeit in lower concentrations than its pregnant counterpart.²⁰ A study by Wang et al²¹ demonstrated that intraoperative infusion of oxytocin significantly reduces blood loss in cases of laparoscopic myomectomy. Currently, there are no existing studies looking at the efficacy of oxytocin infusion in adenomyomectomy. Therefore, the routine use of oxytocin during adenomyomectomy cannot be advocated.

Defect closure

Meticulous and quick stitching for closure by experienced surgeons is the most definitive way to lessen intraoperative blood loss after adenomyomectomy. As in myomectomy, the resulting defect is usually closed with absorbable sutures in one or multiple layers in an interrupted or continuous sequence. The key idea is to close up all the dead spaces so that hematoma formation does not occur.

A useful trick is to approximate the edges with U-shaped sutures, as demonstrated in Figs. 1A and 1B. This approximation serves to reduce tearing of the tissue and reduce tension prior to definitive closure. Sun et al⁸ reported a trend toward decreased blood loss (137 ± 154 mL vs. 216 ± 255 mL; $p = 0.066$) when a U-shaped stitch was placed in the manner described above. The simple explanation could be that the central stitch helped reduce the blood loss through a tamponade effect almost immediately.

Laparoscopic uterine artery occlusion or ligation

The uterus is supplied by the uterine artery, a branch from the anterior division of the internal iliac artery. When occluded,

Table 1
Studies indicating the feasibility of laparoscopic adenomyomectomy.

Study	Cases	Average size of lesion	Average operating time (min)	Average blood loss (mL)	Adjuvants
Morita et al ⁹	3	5.83 cm	91.7	53.3	Preoperative GnRH agonist
Takeuchi et al ¹⁰	14	24 g	101.5	225	Preoperative GnRH agonist (× 9) Oral contraceptive pill (× 1)
Grimbizis et al ¹¹	6	5 cm	100.5	163	Nil
Wang et al ²⁵	2	4.25 cm	NR	NR	Oxytocin infusion for 1 patient
Sun et al ⁸	13	4.4 cm	91	216	Nil
Kang et al ²³	37	60 g	115.7	80.0	Uterine artery occlusion
Overall	61	4–6 cm	99.7	NA	NA

GhRH = gonadotropin-releasing hormone; NA = not applicable; NR = not reported.

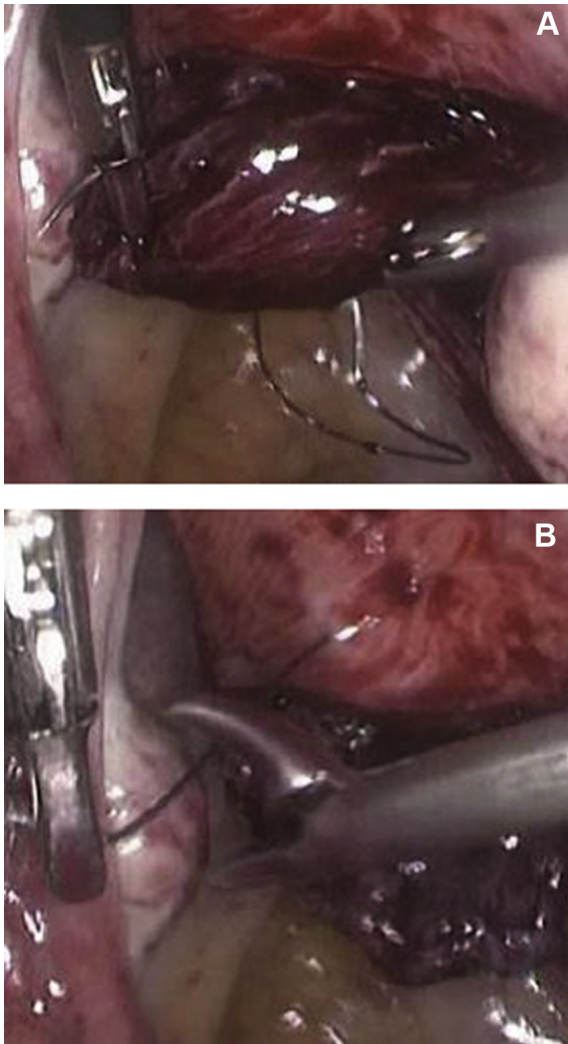


Fig. 1. (A, B) Application of U-shaped sutures to approximate the edges of the adenomyomectomy incision.

transient uterine ischemia occurs, and this has been used extensively in myomectomy procedures to reduce the blood loss.

The uterine arteries can be ligated by an anterior approach or posterior approach.²² In the anterior approach, the uterovesical fold of the peritoneum is first opened and the bladder is pushed down, moving the ureters laterally to prevent them from being included in the sutures (Fig. 2A). The uterine vessels are identified on either side and ligated. In the posterior approach, the uterine artery can be ligated at its origin from the anterior division of the internal iliac after opening the triangle enclosed by the round ligament, external iliac artery, and infundibulopelvic ligament (Fig. 2B).

A retrospective cohort study published by Kang et al²³ looked at the role of uterine artery occlusion in laparoscopic adenomyomectomy. Thirty-seven patients were treated with uterine artery occlusion via the posterior approach, combined with partial resection of adenomyosis via laparoscopy. No severe complications were noted during the surgical procedure or follow-up. The mean surgical time was 115.7 ± 27.5 minutes (mean \pm SD, range 61–171 minutes), and the mean blood loss was 90.0 ± 35.2 mL (range 50–150 mL). At 6 months after surgery, the volume of the uterus shrank 24.7% compared with preoperative volume, and the shrinkage rate was 59.2% at 12 months after surgery.

Studies on uterine artery embolization have stated the possibility of ovarian failure following the procedure.²⁴ Other studies

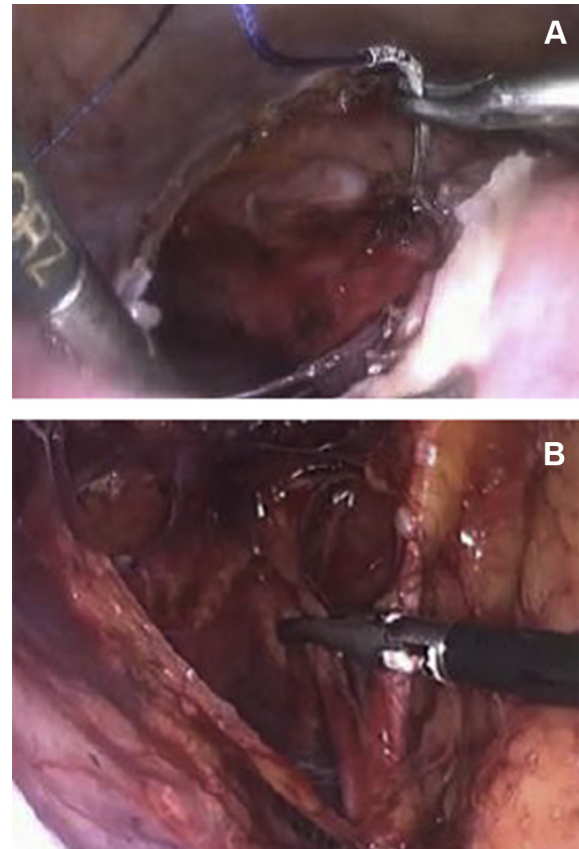


Fig. 2. (A) Ligation of uterine artery—anterior approach. (B) Ligation of uterine artery—posterior approach.

suggest that, unlike uterine artery embolization, uterine artery occlusion is a selective procedure and does not cause decreased ovarian reserve. Qu et al²⁵ conducted a study to assess the effect of ovarian reserve function after laparoscopic uterine artery occlusion, and found that postoperative serum concentrations of follicle-stimulating hormone, luteinizing hormone, and inhibin B in the study group that underwent laparoscopic uterine artery occlusion with myomectomy were not significantly different ($p > 0.5$). When planning surgery for patients desiring fertility, a comprehensive discussion with the patient should be conducted in view of the lack of definitive studies on the effect of uterine artery ligation on future fertility.

Use of tourniquets

There are currently no studies looking specifically at the use of tourniquets for reduction of blood loss in adenomyomectomy procedures. However, the use of tourniquets for occlusion of uterine blood supply has been studied in open myomectomy procedures and has been shown to reduce intraoperative blood loss. The benefit of using a uterine artery tourniquet was illustrated in a randomized trial of 28 women.²⁶

Although there has been a lack of studies looking at tourniquet use in adenomyomectomy, a recent prospective study published in 2013 examined the outcomes of surgical technique of laparoscopic adenomyomectomy with transient occlusion of uterine artery in patients with symptomatic uterine adenomyoma.²⁷ In this study, occlusion of the uterine arteries was done using an endoscopic vascular clip instead of a tourniquet. The mean estimated blood loss was 148.18 ± 93.99 mL, no injury to the uterine arteries or pelvic nerves occurred, and no cases of conversion to a laparotomy or

major complications occurred. The study concluded that laparoscopic adenomyomectomy with transient occlusion of uterine artery could be a safe and effective surgical fertility-preserving method for women with symptomatic uterine adenomyoma. Going by the same principles of occlusion of the uterine arteries, an alternative method of occlusion with tourniquets could produce similar reductions in blood loss.

Timing of surgery

Currently, there are no studies looking at the relationship between timing of adenomyomectomy with regard to the menstrual cycle and intraoperative blood loss, but it is the authors' opinion that the procedure should be performed during the follicular phase of the menstrual period. In addition to preventing the risk of surgery being performed during an undiagnosed luteal phase pregnancy, it has been suggested that the timing of surgery in relation to the menstrual cycle may have an impact on intraoperative blood loss.

A randomized controlled trial by Paraskevaidis et al²⁸ compared the outcomes between patients treated with the loop electro-surgical excision procedure during different phases of the menstrual cycle. It was shown that women treated during the luteal phase experienced significantly more postoperative bleeding. One postulation is that vaginal and pelvic microvessels exhibit increased vascular reactivity during the follicular phase, which allows for better contraction of these microvessels and better hemostasis.

Adhesions

Postoperative adhesions can lead to morbidities such as pain, secondary subfertility, and increased risk of complications in subsequent operations. Although the incidence of adhesions after excision of adenomyomas has not been reported, antiadhesion agents such as Interceed and Seprafilm are still widely used in various types of gynecological surgeries.

Uterine rupture in pregnancy

The expansile capacity of the pregnant uterus depends mostly on an increase in plasticity rather than elasticity,^{29,30} and the main factor determining the increase in plasticity is the collagenous framework of connective tissue.³¹

The safety profile for pregnancy is more defined in laparoscopic myomectomy compared with laparoscopic adenomyomectomy, because the capsule of the myoma demarcates it from normal myometrium. After enucleation and repair of the cavity, the uterus is similar to its original state except for the additional presence of a scar. In adenomyomectomy, it involves actual excision of myometrium fibers, and the resultant uterine scar may also contain foci of adenomyoma that may contribute to weakening of the scar. In this way, repair of the uterus may be less than optimal.

In 2006, Wada et al³² published a case report of a spontaneous uterine rupture of a twin pregnancy after *in vitro* fertilization at 30 weeks of gestation. The patient had suffered from diffuse adenomyosis, and 160 g of adenomyotic fragments was excised posteriorly before closure in two layers. Morimatsu et al³³ reported a similar case of rupture at 28 weeks' gestation, where the patient had undergone a laparoscopic wedge excision for a localized adenomyoma through an incision made in the posterior uterine wall. A single-layer suture repair was performed, and she conceived spontaneously 1 month later.

At present, reports of uterine rupture after adenomyomectomy are scarce, and the true incidence of rupture is yet unknown.

Whether factors such as the size of adenomyoma excised, different stitching techniques, or time to conception after adenomyomectomy affect the risk of uterine rupture is also an unknown. Nevertheless, in view of the debatable benefits of adenomyomectomy if fertility is desired, patients should be counseled preoperatively about the possibility of uterine rupture in future pregnancies so that they may be better informed.

Combined surgical–medical treatment

Adenomyomectomy should not be the be-all and end-all in managing adenomyomas. Prior to making a decision to undertake operative adenomyomectomy, one should consider if conservative medical treatment may alleviate the patient's symptoms without subjecting her to the risks of surgery. In cases where adenomyomectomy has been deemed to be the best management option, consideration should be given to the use of adjuvant medical therapy postoperatively to improve patient outcomes. A study found that a combined surgical–medical treatment in managing symptomatic uterine adenomyomas provided more effective symptom control and a lower symptom relapse rate during a 2-year follow-up period.³⁴

Robotic adenomyomectomy

Following the first case report,⁶ robotic adenomyomectomy widens the options available for excision of localized adenomyosis. At present, robot technology helps in bridging the learning-curve gap between the open and laparoscopic approach. However, aside from the additional drawback of increased operative costs, the challenges inherent to laparoscopy as highlighted earlier are still not fully addressed in robotic surgeries.

Conclusion

The benefits of adenomyomectomy have not yet been definitively established in high-quality studies; therefore, a non-prescriptive approach in managing adenomyomas is recommended. The careful selection of patients is essential to minimize unnecessary morbidities. Proper counseling of patients should include discussions on potential risks and impact on future fertility. The surgical techniques and adjuvants to be used should be varied depending on the patient and disease profile.

Conflicts of interest statement

The authors of this paper certify that they have no affiliations with or involvement in any organisation or entity with any financial interest (such as honoraria; educational grants; participation in speakers' bureaus; membership, employment, consultancies, stock ownership, or other equity interest; and expert testimony or patent-licensing arrangements), or non-financial interest (such as personal or professional relationships, affiliations, knowledge or beliefs) in the subject matter or materials discussed in this manuscript.

References

1. Benson RC, Sneedon VD. Adenomyosis: a reappraisal of symptomatology. *Am J Obstet Gynecol.* 1958;76:1044–1061.
2. Farquhar C, Brosens I. Medical and surgical management of adenomyosis. *Best Pract Res Clin Obstet Gynecol.* 2006;20:603–616.
3. Ferenczy A. Pathophysiology of adenomyosis. *Hum Reprod Update.* 1998;4:312–322.
4. Garcia L, Isaacson K. Adenomyosis: review of the literature. *J Minim Invas Gynaecol.* 2011;18:428–437.

5. Hyama LL. Adenomyosis: its conservative surgical treatment (hysteroplasty) in young women. *N Y J Med.* 1952;52:2778–2783.
6. Akar ME, Leezer KH, Yalcinkaya TM. Robot-assisted laparoscopic management of a case with juvenile cystic adenomyoma. *Fertil Steril.* 2010;94:e55–e56.
7. Reinhold C, McCarthy S, Bret PM, et al. Diffuse adenomyosis: comparison of endovaginal US and MR imaging with histopathologic correlation. *Radiology.* 1996;199:151–158.
8. Sun AJ, Luo M, Wang W, Chen R, Lang JH. Characteristics and efficacy of modified adenomyomectomy in the treatment of uterine adenomyoma. *Chin Med J.* 2011;124:1322–1326.
9. Morita M, Asakawa Y, Nakakuma M, Kubo H. Laparoscopic excision of myometrial adenomyomas in patients with adenomyosis uteri and main symptoms of severe dysmenorrhoea and hypermenorrhoea. *J Am Assoc Gynecol Laparosc.* 2004;11:86–89.
10. Takeuchi H, Kitade M, Kikuchi I, et al. Laparoscopic adenomyomectomy and hysteroplasty: a novel method. *J Minim Invas Gynecol.* 2006;13:150–154.
11. Grimbizis GF, Mikos T, Zepiridis L, et al. Laparoscopic excision of uterine adenomyomas. *Fertil Steril.* 2008;89:953–961.
12. Jin C, Hu Y, Chen XC, et al. Laparoscopic versus open myomectomy—a meta-analysis of randomized controlled trials. *Eur J Obstet Gynecol Reprod Biol.* 2009;145:14–21.
13. Fedele L, Bianchi S, Frontino G. Hormonal treatments for adenomyosis. *Best Pract Res Clin Obstet Gynaecol.* 2008;22:333–339.
14. Kongnyuy EJ, Wiysonge CS. Interventions to reduce haemorrhage during myomectomy for fibroids. *Cochrane Database Syst Rev.* 2011;CD005355.
15. Ginsburg ES, Benson CB, Garfield JM, et al. The effect of operative technique and uterine size on blood loss during myomectomy: a prospective randomized study. *Fertil Steril.* 1993;60:956.
16. Fletcher H, Frederick J, Hardie M, Simeon D. A randomized comparison of vasopressin and tourniquet as hemostatic agents during myomectomy. *Obstet Gynecol.* 1996;87:1014.
17. Zhao F, Jiao Y, Guo Z, et al. Evaluation of loop ligation of larger myoma pseudocapsule combined with vasopressin on laparoscopic myomectomy. *Fertil Steril.* 2011;95:762.
18. Reich H. Laparoscopic myomectomy. *Obstet Gynecol Clin North Am.* 1995;22:757–780.
19. Maggi M, Magini A, Fiscella A, et al. Sex steroid modulation of neurohypophysial hormone receptors in human nonpregnant myometrium. *J Clin Endocrinol Metab.* 1992;74:385–392.
20. Bossmar T, Akerlund M, Szamatowicz J, Laudanski T, Fantoni G, Maggi M. Receptor-mediated uterine effects of vasopressin and oxytocin in nonpregnant women. *Br J Obstet Gynaecol.* 1995;102:907–912.
21. Wang CJ, Lee CL, Yuen LT, Kay N, Han CM, Soong YK. Oxytocin infusion in laparoscopic myomectomy may decrease operative blood loss. *J Minim Invasive Gynecol.* 2007;14:184–188.
22. Rakesh S, Meenakshi S, Chaitali M, Shweta R, Pratima K, Gayatri R. Laparoscopic myomectomy with uterine artery ligation: review article and comparative analysis. *J Gynecol Endosc Surg.* 2011;2:3–10.
23. Kang L, Gong J, Cheng Z, Dai H, Hu L. Clinical application and midterm results of laparoscopic partial resection of symptomatic adenomyosis combined with uterine artery occlusion. *J Minim Invasive Gynecol.* 2009;16:169–173.
24. Tulandi T, Sammour A, Valenti D, Child TJ, Seti L, Tan SL. Ovarian reserve after uterine artery embolisation for leiomyomata. *Fertil Steril.* 2002;78:197–198.
25. Qu X, Cheng Z, Yang W, Xu L, Dai H, Hu L. Controlled clinical trial assessing the effect of laparoscopic uterine arterial occlusion on ovarian reserve. *J Minim Invasive Gynecol.* 2010;17:47–52.
26. Taylor A, Sharma M, Tsirkas P, et al. Reducing blood loss at open myomectomy using triple tourniquets: a randomised controlled trial. *BJOG.* 2005;112:340.
27. Kwon Y-S, Jung D-Y, Lee S-H, Ahn JW, Roh HJ, Im KS. Transient occlusion of uterine arteries with endoscopic vascular clip preceding laparoscopic myomectomy. *J Laparoendosc Adv Sur Tech.* August 2013;23(8):679–683. <http://dx.doi.org/10.1089/lap.2012.0540>.
28. Paraskevaidis E, Davidson EJ, Koliopoulos G, Alamanos Y, Lolis E, Martin-Hirsch P. Bleeding after loop electrosurgical excision procedure performed in either the follicular or luteal phase of the menstrual cycle: a randomized trial. *Obstet Gynecol.* 2002;99:997–1000.
29. Zimmer F. Die plastischen Eigenschaften der Uterusmuskulatur. *Geburtsh Fraenheilk.* 1962;22:1026 [In German].
30. Wood C. The expansile behaviour of the human uterus. *J Obstet Gynecol Br Commonw.* 1964;71:615–620.
31. Harkness MLR, Harkness RD. Changes in the physical properties of the uterine cervix of the rat during pregnancy. *J Physiol (Lond).* 1959;148:524.
32. Wada S, Kudo M, Minakami H. Spontaneous uterine rupture of a twin pregnancy after a laparoscopic adenomyomectomy: a case report. *J Minim Invasive Gynecol.* 2006;13:166–168.
33. Morimatsu Y, Matsubara S, Higashiyama N, et al. Uterine rupture during pregnancy soon after a laparoscopic adenomyomectomy. *Reprod Med Biol.* 2007;6:175–177.
34. Wang PH, Liu WM, Fuh JL, Cheng MH, Chao HT. Comparison of surgery alone and combined surgical–medical treatment in the management of symptomatic uterine adenomyoma. *Fertil Steril.* 2009;92:876–885.
35. Wang CJ, Yuen LT, Chang SD, Lee CL, Soong YK. Use of laparoscopic cytoreductive surgery to treat infertile women with localized adenomyosis. *Fertil Steril.* 2006;86:462.e5–462.e8.