



Short communication

Secure and quick transumbilical initial trocar insertion with skin hooks: The skin hook method



Daisuke Shigemi*, Masao Ichikawa, Shuichi Ono, Katsuya Mine, Shigeo Akira, Toshiyuki Takeshita

Division of Obstetrics and Gynecology, Nippon Medical School, Tokyo, Japan

ARTICLE INFO

Article history:

Received 3 February 2014

Received in revised form
29 May 2014

Accepted 27 August 2014

Available online 8 January 2015

Keywords:

entry technique
optical access system
skin hook
trocar

ABSTRACT

Objective: To evaluate clinical safety and ease of the entry technique using an optical access system and skin hooks.

Materials and methods: A total of 80 gynecological patients who have undergone laparoscopic surgery with either the skin hook method using skin hooks or the conventional method using Pean clamps.

Results: The skin hook method was compared with the conventional method using Pean clamps ($n = 40$ patients each). The skin hook method required less time and there was less device slippage than in the conventional method. No other severe complications occurred after either method.

Conclusion: This method is a simple and secure approach and can be applied during laparoscopic surgery and in patients other than gynecological patients.

Copyright © 2015, The Asia-Pacific Association for Gynecologic Endoscopy and Minimally Invasive Therapy. Published by Elsevier Taiwan LLC. All rights reserved.

Introduction

Laparoscopic surgery has become increasingly popular because of its advantages over conventional laparotomy, including less pain, cosmetic advantages, reduced hospital stay, and faster recovery.^{1,2} To perform gynecological laparoscopy safely, the first step to enter the peritoneal cavity through the umbilicus is important. However, most complications, such as perforation of the intestine or blood vessels, occur at this time.³

During this step, Pean, Kocher, or towel clamps have been used to lift and invert the bottom of the umbilicus before an incision is made to introduce the trocar. However, these clamps often slip from the umbilicus and cause cutaneous damage, which could impair the minimal invasiveness of the laparoscopic procedure and also possibly cause severe complications by the unexpected insertion of the trocar. To date, there is no single secure and minimally invasive method that reduces entry complications and cutaneous scars.

Within our team, Pean forceps have been used to insert the initial trocar, but we have developed a novel technique, the skin hook method, which was designed to reduce the risk of critical complications and the incidence of umbilical damage during first trocar insertion.

Materials and surgical technique

Our team usually inserts the initial transumbilical trocar using an optical access system. The optical trocar allows visualization of the layers of the abdominal wall on monitors. In addition, we used Pean forceps to support the optical access system (hereafter referred as the conventional method).

We used a skin hook with a slight and curved front edge (Fig. 1) in the skin hook method. First, a 3–5-mm incision was made to reach the cutis vera at the bottom of the umbilicus without reversion. Next, two skin hooks were placed at the 3 o'clock and 9 o'clock positions of the umbilical incision. Subsequently, adequate countertraction was applied to the anterior abdominal wall by pulling the skin hooks and grabbing the outside of the abdominal skin by hand to insert the first trocar equipped with a scope (the optical access system using the 5-mm Optiview trocar; Ethicon EndoSurgical Corporation, Cincinnati, OH, USA) (Fig. 2). After

Conflicts of interest: The authors declare no conflicts of interest and received no financial support for this study.

* Corresponding author. Division of Obstetrics and Gynecology, Nippon Medical School Hospital, 1-5 Sendagi 1 chome, Bunkyo-ku, Tokyo 113-0022, Japan.

E-mail address: dshigemi@nms.ac.jp (D. Shigemi).

<http://dx.doi.org/10.1016/j.gmit.2014.08.005>

2213-3070/Copyright © 2015, The Asia-Pacific Association for Gynecologic Endoscopy and Minimally Invasive Therapy. Published by Elsevier Taiwan LLC. All rights reserved.



Fig. 1. Photograph of a skin hook.

Table 1
Baseline characteristics of the enrolled patients.

	Skin hook method (n = 20)	Conventional method (n = 20)	
Age (y)	39.8 ± 6.09	37.5 ± 5.22	p = 0.20
BMI (kg/m ²)	20.95 ± 1.94	21.98 ± 3.96	p = 0.55

BMI = body mass index.

port-site hernia. These procedures were performed in women younger than 50 years.

Clinical data were analyzed using the Fisher test and the Mann–Whitney *U* test.

Results

Statistical analysis showed no significant differences in age or body mass index between both groups (Table 1). The mean (\pm standard deviation) time taken to reach the peritoneal cavity using the skin hook method was significantly shorter compared with the conventional method [92.5 ± 35.2 seconds (range, 35–176) and 122.5 ± 51.1 seconds (range, 74–302), respectively]. Statistical significance was determined using the Mann–Whitney *U* test ($p < 0.05$). A significant difference was found in the frequency of clamp slippage between the skin hook method and the conventional method (0/20 vs. 6/20, respectively; Fisher test: $p < 0.05$). No severe complications occurred using either method.

Discussion

The safety and efficacy of laparoscopic surgery in gynecology have been evaluated using a large amount of clinical data. A meta-analysis of 27 randomized controlled trials comparing laparoscopy

confirming that the scope had reached the peritoneal cavity by video monitor, the skin hooks were removed.

In the conventional method, the umbilicus was reversed by holding the bottom of the umbilicus using Pean forceps. Then, both right and left ends of the umbilicus were held by another two Pean forceps, and a 3–5-mm incision was made using a scalpel. Subsequently, the first trocar using the Optiview trocar was inserted while simultaneously pulling two Pean forceps and grabbing the abdominal skin by hand as previously mentioned.

Three variables of the surgical outcomes of the conventional and skin hook methods ($n = 20$ patients each) were compared: (1) the time of the initial incision to reach the peritoneal cavity; (2) the occurrence of slippage of the skin hooks or Pean forceps; and (3) the occurrence of critical complications such as rupture of larger blood vessels and intestines, trocar site bleeding/infection, and

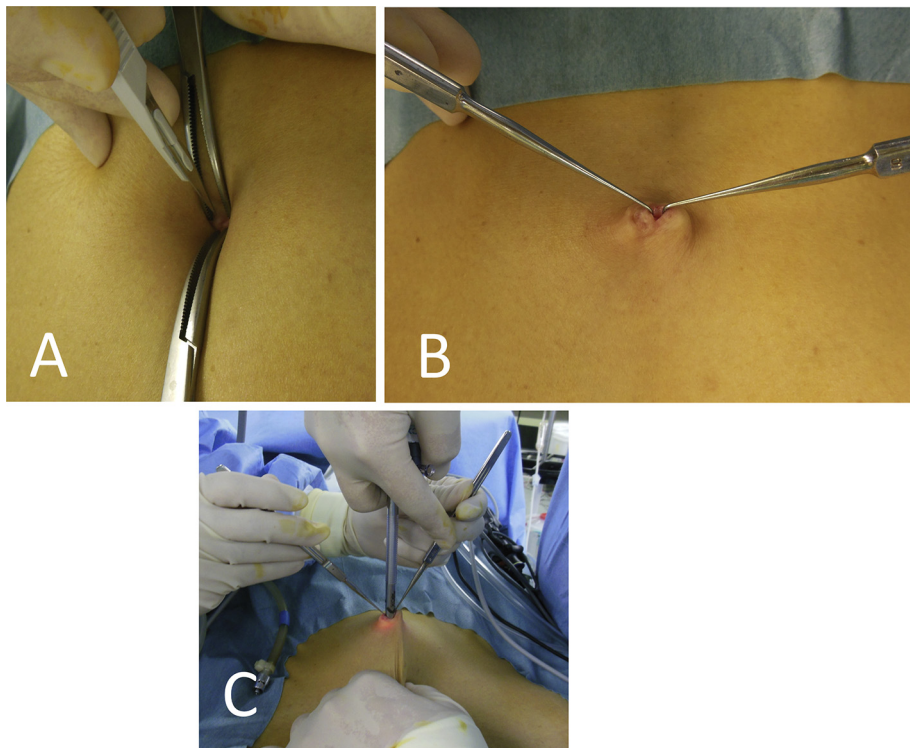


Fig. 2. The skin hook method. (A) A 3–5-mm incision was made to reach the cutis vera at the bottom of the umbilicus. (B) Two skin hooks were placed at the 3 o'clock and 9 o'clock positions of the umbilical incision. (C) Adequate countertraction was applied to the anterior abdominal wall by pulling the skin hooks and grabbing the outside of the abdominal skin by hand to insert the first trocar equipped with a scope (the optical access system).

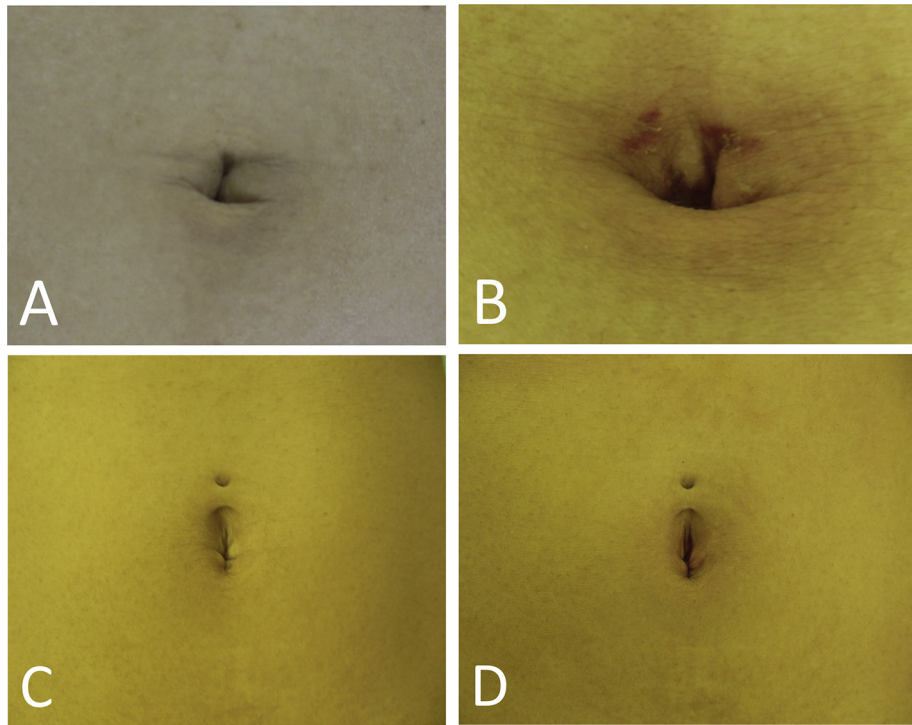


Fig. 3. The umbilicus (A) before and (B) after surgery using the conventional method. There were some visible scars caused by clamping. The umbilicus (C) before and (D) after surgery using the skin hook method. The umbilical wound was virtually invisible.

and laparotomy for benign gynecological procedures has concluded that laparoscopy has fewer minor complications and similar risk of major complications.⁴ Another study has reported that more than 50% of major complications such as bowel and vascular injuries occur prior to the beginning of the planned surgery.^{5,6} In addition, there is no single secure method that reduces entry complications in low-risk patients who have undergone laparoscopic surgery.⁷

As stated already, our team usually uses an optical access system. Optical guidance has been reported to provide a safe and functional primary insertion because each successive layer of the abdominal wall can be seen, so that adhesions can be detected early, thereby preventing injuries to the bowel and abdominal vessels according to some studies.^{8–10}

However, slippage of the clamps often causes damage to the umbilical skin, which could impair the minimal invasiveness of the laparoscopic procedure and also possibly cause severe complications by the unexpected insertion of the trocar.

Here, we evaluated our novel skin hook method and identified several potential advantages. First, successful trocar insertion through the umbilicus, even in patients with a deep navel or hard skin, was relatively simple to perform. Second, the time taken to perform the procedures evaluated in this study did not take longer than the conventional approaches. A major problem with the conventional method is that the device often slips, which can lead to unexpected, severe complications and a noticeable scar. We believe that our new approach can be applied to numerous laparoscopic surgery patients to improve security and postoperative umbilical cosmetic outcomes (Fig. 3). Review articles about abdominal entry in laparoscopic surgery also help when considering what method of first trocar insertion to use.^{11,12}

We have adopted the skin hook method as our standard technique to insert an umbilical trocar, however, further studies are warranted to elucidate its full advantage because the number of patients reviewed might not be sufficient to conclude significant

superiority. In addition, a prospective trial to compare a standardized skin hook method with the conventional method is required to evaluate the objective benefits, such as postoperative pain, recovery, wound complications, patient satisfaction, and cosmetic advantages.

References

- Makinen J, Johansson J, Tomas C, et al. Morbidity of 10110 hysterectomies by type of approach. *Hum Reprod.* 2001;16:1473–1478.
- Johnson N, Barlow D, Lethaby A, Tavender E, Curr L, Garry R. Methods of hysterectomy: systematic review and metaanalysis of randomized controlled trials. *BMJ.* 2005;330:1478.
- Munro MG. Laparoscopic access: complications, technologies, and techniques. *Curr Opin Obstet Gynecol.* 2002;4:365–374.
- Chapron C, Fauconnier A, Goffinet F, Breart G, Dubuisson JB. Laparoscopic surgery is not inherently dangerous for patients presenting with benign gynecologic pathology: results of a meta-analysis. *Hum Reprod.* 2002;17:1334–1342.
- Jansen FW, Kapiteyn K, Trimbo-Kemper T, Hermans J, Trimbo-Kemper JB. Complications of laparoscopy: a prospective multicenter observational study. *Br Obstet Gynaecol.* 1997;104:595–600.
- Jansen FW, Kolkman W, Bakkum EA, de Kroon CD, Trimbo-Kemper TC, Trimbo-Kemper JB. Complications of laparoscopy: an inquiry about closed versus open-entry technique. *Am J Obstet Gynecol.* 2004;190:634–638.
- Ahmad G, O'Flynn H, Duffy JM, Phillips K, Watson A. Laparoscopic entry techniques. *Cochrane Database Syst Rev.* 2012;15:CD006583.
- Jirecek S, Drager M, Leitich H, Nagele F, Wenzl R. Direct visual or blind insertion of the primary trocar. *Surg Endosc.* 2002;16:626–629.
- Wu Shun FW. A safe optically guided entry technique using Endopath Xcel trocars in laparoscopic surgery: a personal series of 821 patients. *Gynecol Min Invas Ther.* 2013;2:30–33.
- String A, Berber E, Foroutani A, et al. Use of the optical access trocar for safe and rapid entry in various laparoscopic procedures. *Surg Endosc.* 2001;15:570.
- Vilos GA, Ternamian A, Dempster J, Laberge PY, The Society of Obstetricians and Gynaecologists of Canada. Laparoscopic entry: a review of techniques, technologies, and complications. *J Obstet Gynaecol Can.* 2007;29:433–465.
- Jongrak T, Kuan-Gen H, Muliati W, Aizura-Syafinaz A, Vahan M, Chyi-Long L. Principles of safe abdominal entry in laparoscopic gynecologic surgery. *Gynecol Min Invas Ther.* 2013;2:105–109.