

Case Report

Laparoscopic Myomectomy of a 4.2 kg Fibroid with Assistance of a Minilaparotomy

Dean Helmar Conrad, Tal Dave Saar, Stefaan Pacqué, Mikhail Sarofim, David Rosen, Gregory Cario, Danny Chou

Sydney Women's Endosurgery Centre, St George Private Hospital, Kogarah, NSW, Australia

Abstract

The improved cosmesis and recovery from minimally invasive techniques has seen a dramatic rise in its popularity. Unfortunately, the laparoscopic myomectomy for large fibroids presents a unique challenge to the surgeon. It is reputed to be difficult and time consuming, with a high risk of conversion to laparotomy. As laparoscopic techniques improve, the laparoscopic myomectomy for larger fibroids is becoming more feasible. This article outlines the case of laparoscopic removal of a 4.2 kg fibroid with the assistance of a minilaparotomy.

Keywords: Fibroids, laparoscopic myomectomy, large myomas, uterine artery ligation

INTRODUCTION

Leiomyoma or uterine fibroids are the most common benign tumors of the uterus affecting up to 25% of reproductive age women.^[1] Most uterine fibroids are asymptomatic and do not require investigation or intervention.^[2] When they do cause problems, symptoms can be debilitating, ranging from bleeding and pain to urinary urgency and infertility.^[3] Management of fibroids depends on their size, location, degree of symptoms, and desire to conceive. For multiple or large symptomatic fibroids, abdominal hysterectomy is considered the gold standard treatment. It is the only treatment which offers a definitive solution, with no risk of recurrence.^[4] However, for women wishing to preserve their uterus, options are more limited. Medical management is available; however, cost and side effects of medical therapies may limit their long-term use.^[2] Laparoscopic myomectomy is the best treatment option for symptomatic women with uterine fibroids who wish to maintain their fertility. Compared to the open procedure, the laparoscopic approach allows shorter hospital stays, less postoperative pain, and rapid recovery with less adhesion formation while providing an assessment of other organs.^[5] However, the laparoscopic myomectomy is a more technically demanding and complex surgical procedure with a long learning curve, higher blood loss, longer operating time, and a notable number of conversions to open surgery.^[6] This case report will

outline some of the challenges facing surgeons performing laparoscopic removal of very large fibroids.

CASE REPORT

This is the case of a 45 year old nulliparous female requesting laparoscopic removal of her large uterine fibroid. The mass had been present for several years, growing steadily over that time. Her main presenting complaints were pain and discomfort as well as increasing menorrhagia. She had seen a gynecologist 2 years prior, and after refusing a hysterectomy, she underwent uterine artery embolization. Uterine arteries were obstructed bilaterally using histoacryl-lipiodol glue, which slightly improved her menorrhagia although failed to decrease the size of the fibroid or associated symptoms of discomfort. She is a nonsmoker with a background of obesity as well as anxiety and depression which were not medicated. She also has impaired glucose tolerance managed conservatively. Her recent PAP smear was normal.

Examination revealed a large mass arising from the pelvis to approximately 15 cm above the umbilicus. Both magnetic

Address for correspondence: Dr. Dean Helmar Conrad,
St George Private Hospital, Gray Street, Kogarah, NSW 2217, Australia.
E-mail: deanconrad@gmail.com

Access this article online

Quick Response Code:



Website:
www.e-gmit.com

DOI:
10.4103/GMIT.GMIT_13_18

This is an open access journal, and articles are distributed under the terms of the Creative Commons Attribution-NonCommercial-ShareAlike 4.0 License, which allows others to remix, tweak, and build upon the work non-commercially, as long as appropriate credit is given and the new creations are licensed under the identical terms.

For reprints contact: reprints@medknow.com

How to cite this article: Conrad DH, Saar TD, Pacqué S, Sarofim M, Rosen D, Cario G, *et al.* Laparoscopic myomectomy of a 4.2 kg fibroid with assistance of a minilaparotomy. *Gynecol Minim Invasive Ther* 2018;7:130-2.

resonance imaging (MRI) and ultrasound demonstrated a 23 cm × 16 cm × 22 cm subserosal fibroid arising from the left lateral uterine wall. The patient was adamant about retaining her uterus and had seen four surgeons previously regarding the role of laparoscopic surgery.

The patient was bowel prepped with PicoPrep and kept on a liquid diet for 2 days to ensure complete bowel emptying. Preoperative hysteroscopy was performed to assess the cavity and exclude a malignancy. The procedure was performed under general anesthesia with endotracheal intubation. The patient was placed in dorsal lithotomy and a Foley's catheter was inserted (and kept in place for 24 h) before a uterine manipulator was inserted. Abdominal access was gained through Hasson open entry with 12 mm intraumbilical incision. Following pneumoperitoneum to 15 mmHg, a 10 mm port at the xiphisternum was placed under vision, allowing a more panoramic view. A 10 mm 30° laparoscope was used to enable adequate vision. An additional 5 mm suprapubic and two 5 mm left and right lower lateral ports were inserted under vision. A massive uterine fibroid was noted arising from the left lateral aspect of the uterus extending retroperitoneally into the left broad ligament and paracolic gutter displacing the sigmoid colon medially. Her ovaries and tubes bilaterally appeared normal. The right uterine artery was identified through a transverse incision in the anterior leaflet of the broad ligament to enter the paravesical space, with the right round ligament kept intact. Five-millimeter Ligaclips were used for uterine artery ligation [Figure 1]. The left round ligament was transected with bipolar and scissors and the broad ligament opened. The left uterine artery was identified in the paravesical space and similarly ligated. The retroperitoneal space was further developed exposing the fibroid through extending the peritoneal incision with bipolar and scissors. Dissection of the fibroid from the pelvic sidewall revealed a large subserosal fibroid with attachment arising from the left posterolateral aspect of the uterus. The 5 mm suprapubic port was then opened to approximately 5 cm. The fibroid pedicle was grasped with toothed graspers and detached from

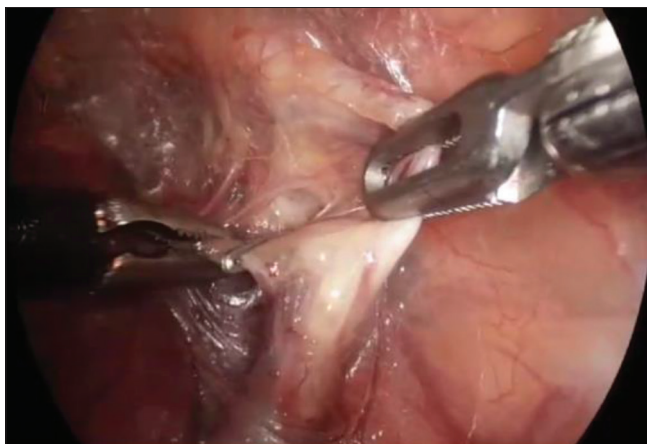


Figure 1: Ligation of the right uterine artery

the uterus with a scalpel. The fibroid was morcellated using a scalpel and removed through the abdominal incision. The myometrium was repaired in layers with 0 V-Loc (Covidien, Mansfield, MA, USA), and the uterine serosa approximated with the use of a “baseball” stitch. After hemostasis was confirmed with bipolar diathermy, Interceed adhesion barrier was applied (Ethicon, Johnson and Johnson, Neuchatel, Switzerland). The sheath was closed with continuous 0 PDS and skin secured with subcuticular 3-0 monocryl sutures.

The estimated blood loss was 300 ml, and the procedure lasted 180 min. The total weight of the morcellated fibroid was 4.2 kg and histology confirmed benign leiomyoma. The patient made an uneventful recovery and was discharged home day 2 postoperatively.

DISCUSSION

Opinions vary regarding the feasibility of laparoscopic myomectomy for large myomas. Limits of the size and number of myomas beyond which laparoscopic removal is contraindicated have been proposed.^[7] Some authors maintain strict criteria for laparoscopic myomectomy, including a fibroid of <15 cm in size, and no more than three fibroids with a size of 5 cm.^[4] With increasing demands for uterine preservation and less invasive management, patients are expecting more from their surgeons. Although laparoscopic instruments and techniques are constantly improving, hemostasis, uterine closure, and removal of tissue remain as barriers to this difficult operation.

The tendency for bleeding poses significant difficulties, especially with the very large fibroid. The higher rates of conversion to open laparotomy are mostly attributed to intraoperative bleeding.^[8] A number of techniques have been outlined in the literature for overcoming issues with hemostasis. Several successful case reports document combining concurrent use of uterine artery embolization.^[9] Risks such as increased miscarriage and preterm delivery rates as well as loss of ovarian reserve limit its application for women wishing to conceive.^[4] Laparoscopic uterine artery occlusion was first detailed in 2001 and associated with a marked decrease in blood loss.^[10] Although one would postulate that a pregnancy following such a procedure would have an increased risk of miscarriage and preterm delivery,^[11] there is evidence to suggest that the long-term uterine artery flow is maintained post uterine artery clipping.^[12] A transient uterine artery occlusion approach has been developed and may offer the advantages of reduced blood loss without any long-term consequences of uterine ischemia.^[13] Vasopressin, although off label for this use, has been well documented in its role as a vasoconstrictor preinjected into incision site. It improves the surgeons' ability to develop tissue planes and compresses vessels minimizing bleeding and facilitating fibroid enucleation.^[14]

Uterine closure is another significant barrier for the laparoscopic surgeon. Intracorporeal suturing remains one

of the most difficult skills to master, and appropriate uterine closure is critical for future pregnancy outcomes.^[8] The development of self-locking barbed sutures such as V-Loc™ 180 (Covidien, Mansfield, MA, USA) provides a simpler method of closing the myometrium. However, long-term data for this suture are yet to be established.

Tissue retrieval presents a unique challenge in the laparoscopic myomectomy. Morcellation has undergone recent scrutiny due to the risk of inadvertent dissemination of uterine sarcoma. Although this condition is rare, occurring in approximately 3–7/100,000 women in the United States,^[16] it has a poor prognosis made worse through morcellation.^[17] Although detailed preoperative workup including menopausal status and imaging with MRI allows high-risk patients to be identified, not all cancers can be excluded. The use of contained power morcellation within an insufflated bag has been outlined as a safer alternative.^[18] However, the size of the bag limits its usefulness in the very large fibroid. Cold-knife morcellation in theory has a reduced risk of tissue dissemination compared to electromechanical morcellation although there are no data on the comparative risk of surgical methods. Combining cold-knife morcellation with the mini- and ultraminilaparotomic myomectomy allows for quicker and potentially safer tissue retrieval.^[15]

CONCLUSION

Advancements in laparoscopic techniques have seen the laparoscopic myomectomy for larger fibroids become a more feasible alternative to the open procedure in women wishing to preserve their uterus. Although hemostasis, uterine closure, and tissue removal remain as barriers to successful laparoscopic myomectomy, with the requisite skill and adequate support, the size of the myomas needs not be a limiting factor for the procedure.

Declaration of patient consent

The authors certify that they have obtained all appropriate patient consent forms. In the form the patient(s) has/have given his/her/their consent for his/her/their images and other clinical information to be reported in the journal. The patients understand that their names and initials will not be published and due efforts will be made to conceal their identity, but anonymity cannot be guaranteed.

Acknowledgment

The authors thank Professor Felix Wong for his editorial assistance in the preparation of this manuscript.

Financial support and sponsorship

Nil.

Conflicts of interest

There are no conflicts of interest.

REFERENCES

1. Buttram VC Jr., Reiter RC. Uterine leiomyomata: Etiology, symptomatology, and management. *Fertil Steril* 1981;36:433-45.
2. Lefebvre G, Vilos G, Allaire C, Jeffrey J, Arneja J, Birch C, *et al.* The management of uterine leiomyomas. *J Obstet Gynaecol Can* 2003;25:396-418.
3. Solomon LA, Schimp VL, Ali-Fehmi R, Diamond MP, Munkarah AR. Clinical update of smooth muscle tumors of the uterus. *J Minim Invasive Gynecol* 2005;12:401-8.
4. Agdi M, Tulandi T. Endoscopic management of uterine fibroids. *Best Pract Res Clin Obstet Gynaecol* 2008;22:707-16.
5. Hurst BS, Matthews ML, Marshburn PB. Laparoscopic myomectomy for symptomatic uterine myomas. *Fertil Steril* 2005;83:1-23.
6. Darai E, Deval B, Darles C, Benifla JL, Guglielmina JN, Madelenat P, *et al.* Myomectomy: Laparoscopy or laparotomy. *Contracept Fertil Sex* 1996;24:751-6.
7. Dubuisson JB, Chapron C, Levy L. Difficulties and complications of laparoscopic myomectomy. *J Gynecol Surg* 1996;12:159-65.
8. Sinha R, Sundaram M. Laparoscopic management of large myomas. *J Gynecol Endosc Surg* 2009;1:73-82.
9. Tixier H, Loffroy R, Filipuzzi L, Grevoul J, Mutamba W, Cercueil J, *et al.* Uterine artery embolization with resorbable material prior to myomectomy. *J Radiol* 2008;89:1925-9.
10. Liu WM, Ng HT, Wu YC, Yen YK, Yuan CC. Laparoscopic bipolar coagulation of uterine vessels: A new method for treating symptomatic fibroids. *Fertil Steril* 2001;75:417-22.
11. Holub Z, Mara M, Kuzel D, Jabor A, Maskova J, Eim J, *et al.* Pregnancy outcomes after uterine artery occlusion: Prospective multicentric study. *Fertil Steril* 2008;90:1886-91.
12. Rosen DM, Hamani Y, Cario GM, Chou D. Uterine perfusion following laparoscopic clipping of uterine arteries at myomectomy. *Aust N Z J Obstet Gynaecol* 2009;49:559-60.
13. Liu L, Li Y, Xu H, Chen Y, Zhang G, Liang Z, *et al.* Laparoscopic transient uterine artery occlusion and myomectomy for symptomatic uterine myoma. *Fertil Steril* 2011;95:254-8.
14. Cohen SL, Wang KC, Gargiulo AR, Srouji S, Goggins ER, Solnik J, *et al.* Vasopressin administration during laparoscopic myomectomy: A Randomized controlled trial. *J Minim Invasive Gynecol* 2015;22:S39.
15. Ciavattini A, Tsioglou D, Tranquilli AL, Litta P. Laparoscopic versus ultraminilaparotomic myomectomy for the treatment of large uterine myomas. *Acta Obstet Gynecol Scand* 2010;89:151-5.
16. Brooks SE, Zhan M, Cote T, Baquet CR. Surveillance, epidemiology, and end results analysis of 2677 cases of uterine sarcoma 1989-1999. *Gynecol Oncol* 2004;93:204-8.
17. Park JY, Park SK, Kim DY, Kim JH, Kim YM, Kim YT, *et al.* The impact of tumor morcellation during surgery on the prognosis of patients with apparently early uterine leiomyosarcoma. *Gynecol Oncol* 2011;122:255-9.
18. Leal MA, Piñera A, De Santiago J, Zapardiel I. Novel technique for contained power morcellation through umbilicus with insufflated bag. *Gynecol Obstet Invest* 2017;82:205-7.