

Case Report

Laparoscopic Surgery for Ovarian Epidermoid Cyst with Preservation of Ovarian Function

Ryo Yokomizo, Akihiko Misawa, Miki Muto, Akari Nakajima, Akinobu Izumi, Seika Nagae, Nami Yamamura, Suguru Odajima, Akiko Tanuma Takahashi

Department of Obstetrics and Gynecology, Chigasaki Municipal Hospital, Chigasaki, Japan

Abstract

Ovarian epidermoid cyst, an extremely rare tumor occurring mostly in older females, is lined by mature stratified squamous epithelium and distinguishable from mature teratoma by the absence of skin adnexae and other tissues. In imaging, these tumors resemble solid tumors, necessitating most patients to undergo oophorectomy to verify malignancy. We herein present the case of an ovarian epidermoid cyst in a pregnant woman who underwent laparoscopic cystectomy after delivery with preserved ovarian function. To the best of our knowledge, this is the first case report of an ovarian epidermoid cyst that was detected during pregnancy and treated with laparoscopic cystectomy. Preservation of ovarian function and application of minimally invasive surgery should be strongly considered in young patients with ovarian epidermoid cysts.

Keywords: Fertility preservation, laparoscopy, ovarian epidermoid cyst, pregnancy, solid tumor

INTRODUCTION

Epidermoid cysts are an extremely rare pathological type of ovarian tumor that is lined by mature stratified squamous epithelium and are distinguished from mature teratomas by the absence of skin adnexae and other tissues.^[1] Most cases of ovarian epidermoid cysts occur in older women and are incidentally detected during examination of hysterectomy specimens.^[2] In previous reports, almost all patients with epidermoid cysts underwent conventional laparotomy and oophorectomy to verify the presence of malignancy due to the resemblance of the cyst to a solid tumor in imaging.^[2-5] However, epidermoid cysts are histopathologically benign ovarian tumors, and minimally invasive surgery should be considered when removing epidermoid cysts in young patients to preserve ovarian function.^[6] In this report, we present the case of a pregnant woman with an ovarian epidermoid cyst who underwent total laparoscopic cystectomy after delivery with preserved ovarian function.

CASE REPORT

A 36-year-old gravida 4 para 1 female was presented to our hospital with 7 weeks of amenorrhea and positive for pregnancy test. After menarche at the age of 14 years, her menstrual cycles were regular and occurred approximately every 30 days with menstrual periods

lasting 5 days. Her body mass index was 30.7 kg/m². Transvaginal ultrasonography (TVUS) revealed a gestational sac and fetus in uterus and a solid mass of approximately 5 cm in diameter in the right ovary. The primary clinical course of her pregnancy was good, and magnetic resonance imaging (MRI) was performed at 12 weeks of gestation to assess the solid mass. MRI revealed diffuse enlargement of the right ovary with iso-intensity-to-low intensity on T1-weighted images, heterogeneous relatively high intensity on T2-weighted images, high-intensity signals on diffusion-weighted imaging (DWI), and a low apparent diffusion coefficient (ADC) value [Figure 1a-d]. The laboratory values were within normal limits, including those of tumor markers (e.g., carbohydrate antigen 125, carbohydrate antigen 19-9, and carcinoembryonic antigen). Based on these findings, a stromal tumor with a low possibility of malignancy was suspected, and the patient was followed up with TVUS and observation during pregnancy. There was no change in size or characteristics of the tumor with TVUS throughout her pregnancy.

Address for correspondence: Dr. Ryo Yokomizo,

Department of Obstetrics and Gynecology, Chigasaki Municipal Hospital, 5-15-1, Honson, Chigasaki, Kanagawa, 253-0042, Japan.

E-mail: ryokomizo1006@gmail.com

This is an open access article distributed under the terms of the Creative Commons Attribution-NonCommercial-ShareAlike 3.0 License, which allows others to remix, tweak, and build upon the work non-commercially, as long as the author is credited and the new creations are licensed under the identical terms.

For reprints contact: reprints@medknow.com

How to cite this article: Yokomizo R, Misawa A, Muto M, Nakajima A, Izumi A, Nagae S, *et al.* Laparoscopic surgery for ovarian epidermoid cyst with preservation of ovarian function. *Gynecol Minim Invasive Ther* 2018;7:40-3.

Access this article online

Quick Response Code:



Website:
www.e-gmit.com

DOI:
10.4103/GMIT.GMIT_2_17

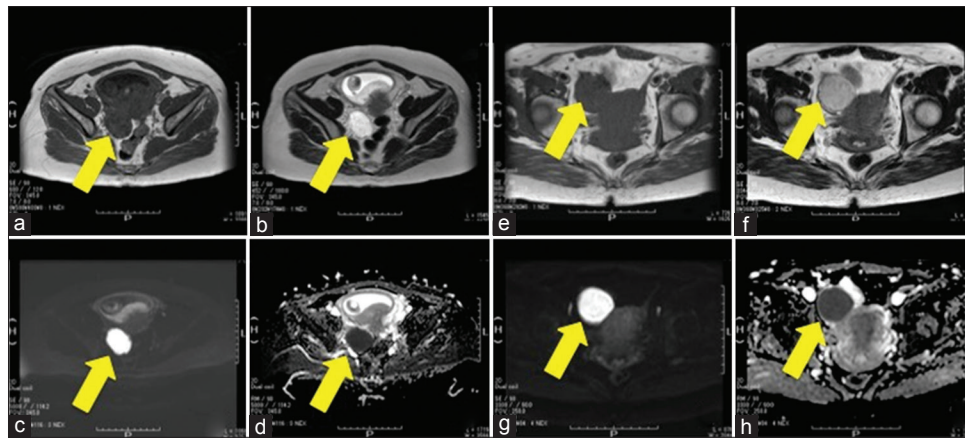


Figure 1: Magnetic resonance imaging studies of the pelvis in the present case. (a), (b), (c), and (d) Magnetic resonance imaging performed at 12 weeks of gestation. (e), (f), (g), and (h) magnetic resonance imaging performed at 2 months after delivery. (a) Axial T1-weighted image showing an enlarged right ovary (arrow) with iso intensity to low intensity. (b) Axial T2-weighted image showing an enlarged right ovary (arrow) with relatively high intensity. (c) Axial diffusion-weighted imaging showing an enlarged right ovary (arrow) with increased signal intensity. (d) Axial apparent diffusion coefficient showing an enlarged right ovary (arrow) with low-signal intensity. (e) Axial T1-weighted image showing an enlarged right ovary (arrow) with iso intensity to low intensity. (f) Axial T2-weighted image showing an enlarged right ovary (arrow) with somewhat lower intensity than the image presented in (b). (g) Axial diffusion-weighted imaging showing an enlarged right ovary (arrow) with high-signal intensity. (h) Axial apparent diffusion coefficient showing an enlarged right ovary (arrow) with low-signal intensity

At 40 weeks and 1 days of pregnancy, the patient was admitted to our hospital due to premature rupture of membranes and spontaneously delivered a male baby vaginally. The baby's birth weight was 2885 g, and his Apgar score was 8 at 1 min and 9 at 5 min. The postpartum clinical course for the mother and baby were unremarkable.

A month after delivery, TVUS was performed in the outpatient clinic for follow-up of the ovarian mass and revealed a solid mass in the right ovary measuring approximately 5 cm in diameter. MRI was performed repeatedly at 2 months after delivery MRI revealed that the diameter of the solid mass in the right ovary was approximately 5 cm and had iso intensity- to low intensity on T1-weighted images. The mass showed a somewhat lower intensity on T2-weighted images compared with the previous MRI (normalized T2 values of the mass were between about 2500 ms and 2900 ms with the previous MRI, in contrast, those were between about 700 ms and 900 ms with this MRI) and also showed a high-intensity signal on DWI and a low ADC value [Figure 1e-h]. Due to the possibility of malignancy associated with a solid tumor and the change in the signal pattern by MRI during pregnancy, surgical management was considered. Due to the young age of the patient, minimally invasive surgery with laparoscopy was planned. In operation, we placed a 3-cm incision along to the annulus umbilicalis for insertion of LAP DISC® (Hakko) and EZ Access® (Hakko). During surgery, a soft, egg-sized ovarian tumor with a smooth surface was identified in the right ovary [Figure 2a]. The tumor ruptured and could easily be separated from the normal ovarian tissue by forceps intraperitoneally and was carried out from the incision; therefore, total laparoscopic cystectomy was performed, and tumor dissection revealed a cream-colored irregular mass [Figure 2b]. Histopathological examination revealed that the cyst wall was lined by mature stratified

squamous epithelium without skin adnexae and other tissues, and histopathological diagnosis revealed an epidermoid cyst with no malignant findings [Figure 2c].

The patient was discharged 3 days after surgery without complications. The right ovary returned to a normal size, and there was no evidence of recurrence based on ultrasonography. Six months after surgery, she achieved a spontaneous pregnancy.

DISCUSSION

The ovarian epidermoid cyst was first reported by Nogales and Silverberg in 1976.^[7] According to the World Health Organization (WHO) histological classification of tumors of the ovary, epidermoid cysts are classified as squamous cell tumors.^[6] Epidermoid cysts are defined as benign ovarian cysts lined by squamous epithelial cells that are clearly not of germ cell origin.^[6] Regarding histopathological features, ovarian epidermoid cysts comprise <1% of ovarian surface epithelial tumors,^[8] and the mechanism of histogenesis remains unclear. Peters *et al.*^[9] suggested that ovarian epidermoid cysts commonly originated from pluripotential celomic epithelium. Young *et al.*^[10] suggested that ovarian epidermoid cysts originated from epithelial cell nests using the same mechanism as Brenner tumors. The histopathological differential diagnosis of ovarian epidermoid cysts includes mature teratoma of the ovary. Both mature teratomas and epidermoid cysts are benign ovarian tumors; however, they are classified into different categories of tumors of the ovary by WHO.^[6] Therefore, precise classification of these tumors is necessary.

According to Kondi-Pafiti *et al.*,^[8] most ovarian epidermoid cysts occur in older women, with an average age of 55 years (range, 17–69 years), and all ovarian epidermoid

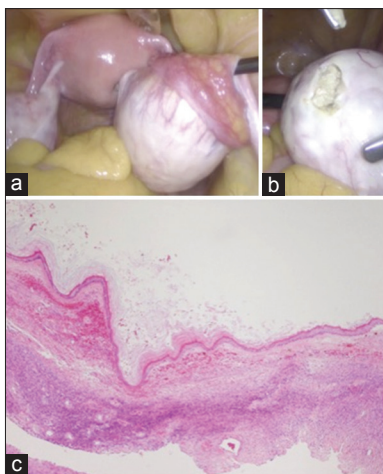


Figure 2: Laparoscopic view and pathological findings of the right ovarian cyst. (a) Uterus and ovaries. The right ovary being enlarged to egg size. (b) Incision to the surface of the right ovarian cyst revealing a cream-colored irregular mass. (c) Pathological findings of the right ovarian cyst with h and e staining. Wall of the cyst is lined by mature stratified squamous epithelium without skin adnexae and other tissues. Original magnification, $\times 4$

cysts develop unilaterally. The mean diameter of the tumors was 3.9 cm (range, 2.3–7.4 cm). Symptoms included abdominal pain and abdominal distension; however, the most common symptom was abdominal pain with pelvic mass.^[8] Our patient was a 36-year-old and did not have specific symptoms. Considering the clinical characteristics of ovarian epidermoid cysts, the patient did not exhibit typical clinical manifestations, which contributed to a challenging preoperative diagnosis.

There are currently no clear diagnostic criteria for ovarian epidermoid cysts. Typical MRI findings of ovarian epidermoid cysts are an enlarged ovary with low intensity or iso intensity on T1-weighted images and heterogeneous, solid-like high intensity on T2-weighted images.^[3] Based on these imaging characteristics, stromal tumors such as thecomas and fibromas are included in differential diagnosis. For definitive diagnosis, the fat saturation method is suggested as a useful tool to aid in the differential diagnosis between epidermoid cysts and mature teratomas as no suppression is observed with the fat saturation method in epidermoid cysts.^[3] In the present case, the fat saturation method was not conducted because the tumor appeared as a solid tumor, and the possibility of mature teratoma was not considered. There are no studies on ovarian epidermoid cysts which have reported signal changes by MRI during pregnancy. Hormonal changes during pregnancy might affect the tumor contents; however, there is no scientific literature supporting this possibility due to the rarity of this tumor. Further evaluation and report of additional cases are required.

According to the previous reports, the most commonly performed treatment for ovarian epidermoid cysts is oophorectomy by conventional laparotomy.^[2-5] In many

cases, ovarian epidermoid cysts were incidentally identified in patients who underwent hysterectomy for other medical conditions.^[2] However, we should consider whether oophorectomy is the best treatment for young patients. Because ovarian epidermoid cysts are benign, it is critical to avoid unnecessary oophorectomy in these patients.^[6] Furthermore, laparoscopic surgery should be considered for ovarian cysts in young patients to ensure prevention of postoperative adhesions and facilitation of easier conception and esthetic outcomes for these patients.

Intraoperative findings were useful to determine the method of surgical removal of the tumor in our patient. During laparoscopic surgery, the surface of the ovarian tumor was pushed by forceps, and a wave-like movement was observed. This observation was considered to be atypical for solid tumors; therefore, cystectomy was performed. The contents of ovarian epidermoid cysts were previously reported to include white flakes of keratin.^[5] In the present case, the contents of the ovarian tumor had a similar characteristic [Figure 2b], which led to the intraoperative finding of wave-like movement.

CONCLUSION

Ovarian epidermoid cysts should be considered for the differential diagnosis of solid ovarian tumors. For best outcomes, preservation of ovarian function and application of minimally invasive surgery should be considered in young women with ovarian epidermoid cysts. Although ovarian epidermoid cysts are rare tumors, unnecessary surgical approaches such as oophorectomy should be avoided.

Acknowledgments

This manuscript was reviewed for concise English language by a native English editing service (Enago).

Declaration of patient consent

The authors certify that they have obtained all appropriate patient consent forms. In the form the patient(s) has/have given his/her/their consent for his/her/their images and other clinical information to be reported in the journal. The patients understand that their names and initials will not be published and due efforts will be made to conceal their identity, but anonymity cannot be guaranteed.

Financial support and sponsorship

Nil.

Conflicts of interest

There are no conflicts of interest.

REFERENCES

1. Rosai J. Rosai and Ackerman's Surgical Pathology. 10th ed. Amsterdam, Netherlands: Elsevier Health Sciences; 2011. p. 1590.
2. Pezzica E, Buzzi A, Crescini C. Epidermoid cysts of the ovary. Presentation of a case of unusual dimensions. *Minerva Ginecol* 1991;43:265-6.
3. Shinya T, Joja I, Hashimura S, Hayashi H, Gobara H, Kato K, *et al.* Magnetic resonance imaging features of epidermoid cyst of the ovaries:

- Magnetic resonance and computed tomography findings. *J Comput Assist Tomogr* 2006;30:906-9.
4. Veena S, Vijay PM, Sowmya S. Pure epidermoid cyst of ovary. *J Cancer Res Ther* 2015;11:1046.
 5. Sharma N, Manimekalai, Sonti S, Meenakshisundaram. A rare case of a giant epidermoid cyst of the ovary. *J Clin Diagn Res* 2012;6:1584-6.
 6. Tavassoli FA, Devilee P, editors. *Pathology and Genetics of Tumours of the Breast and Female Genital Organs*. Lyon, France: IARC Press; 2003. p. 114-44.
 7. Nogales FF Jr., Silverberg SG. Epidermoid cysts of the ovary: A report of five cases with histogenetic considerations and ultrastructural findings. *Am J Obstet Gynecol* 1976;124:523-8.
 8. Kondi-Pafiti A, Filippidou-Giannopoulou A, Papakonstantinou E, Iavazzo C, Grigoriadis C. Epidermoid or dermoid cysts of the ovary? Clinicopathological characteristics of 28 cases and a new pathologic classification of an old entity. *Eur J Gynaecol Oncol* 2012;33:617-9.
 9. Peters K, Gassel AM, Müller T, Dietl J. Ovarian epidermoid cyst and endometrioid carcinoma: Do they share their origin?. *Zentralbl Gynakol* 2002;124:443-5.
 10. Young RH, Prat J, Scully RE. Epidermoid cyst of the ovary. A report of three cases with comments on histogenesis. *Am J Clin Pathol* 1980;73:272-6.

