



Contents lists available at ScienceDirect

Gynecology and Minimally Invasive Therapy

journal homepage: www.e-gmit.com

Case report

Laparoscopically assisted cervical canalization and neovaginoplasty in a woman with cervical atresia and vaginal aplasia



Asami Kobayashi, Atsushi Fukui*, Ayano Funamizu, Asami Ito, Rie Fukuhara, Hideki Mizunuma

Department of Obstetrics and Gynecology, Hirosaki University Graduate School of Medicine, Hirosaki, Aomori, Japan

ARTICLE INFO

Article history:

Received 24 December 2015

Received in revised form

6 May 2016

Accepted 9 May 2016

Available online 7 June 2016

Keywords:

cervical atresia
cervical canalization
laparoscopy
neovaginoplasty
vaginal aplasia

ABSTRACT

Cervical atresia is a Müllerian duct system anomaly, and it is often associated with vaginal aplasia. We report the case of a 17-year-old girl who presented with primary amenorrhea and cyclical abdominal pain, and was diagnosed with cervical atresia and vaginal aplasia that were treated laparoscopically. Laparoscopically assisted cervical canalization and neovaginoplasty were performed to relieve dysmenorrhea and allow for sexual intercourse and fertility. We did not use a bowel segment, skin, or peritoneum as a graft for the neovaginoplasty. To prevent adhesions and promote epithelialization, we used an estrogen-containing cream. Moreover, we did not use a vaginal mold. The patient is free of cervical stenosis and able to have intercourse. Long-term follow-up is necessary to ensure a future pregnancy and childbirth.

Copyright © 2016, The Asia-Pacific Association for Gynecologic Endoscopy and Minimally Invasive Therapy. Published by Elsevier Taiwan LLC. This is an open access article under the CC BY-NC-ND license (<http://creativecommons.org/licenses/by-nc-nd/4.0/>).

Introduction

Cervical atresia is a Müllerian duct anomaly, and it is often associated with vaginal aplasia.¹ It is extremely rare, and although various surgical techniques have been reported, the method of choice remains controversial.^{2–4}

We report the case of a patient with a cervical atresia and vaginal aplasia who was treated laparoscopically. Written informed consent was obtained from the patient for publication of this case report. The local institutional review board exempted our case from the need for approval.

Case report

A 17-year-old Japanese girl visited a local hospital because of primary amenorrhea and cyclical abdominal pain for more than 5 months. The transabdominal ultrasound revealed a hematometra. Only the vaginal opening, without the vaginal cavity, was seen

while inspecting the vulva. A magnetic resonance imaging examination also revealed cervical atresia and vaginal aplasia, and hemorrhagic ascites. She was referred to our hospital for further evaluation and treatment.

A transectal ultrasound and magnetic resonance imaging showed a normal body of the uterus, the endometrium, and ovaries; however, the uterine part of the cervix was observed to be tapering at the inferior end (Figure 1A). She experienced cyclic lower abdominal pain concurrent with a drop in basal body temperature. At that time, a hematometra and an accumulation of fluid in the peritoneal cavity were detected. Laparoscopically assisted cervical canalization and neovaginoplasty were performed to relieve dysmenorrhea, and allow for sexual intercourse and fertility.

The surgery was scheduled during the menstruation, because a hematometra allows for an easy detection of the uterine cavity and makes it safe to perform a mechanical dilatation of the cervix. The body of the uterus and bilateral adnexa were normal; however, the uterine part of the cervix was thin and short (Figure 1B). Mild endometriosis was detected on the pelvic peritoneum.

First, we constructed a neovagina through the vulva.

Briefly, an X-shaped incision of the hymen was made, and a neovagina was manually constructed between the bladder and the rectum. The uterine cervix was small, and the external os was not visualized. To reveal it, the uterus was opened at the fundus using a

Conflicts of interest: The authors have no conflicts of interest relevant to this article.

* Corresponding author. Department of Obstetrics and Gynecology, Hirosaki University Graduate School of Medicine, 5 Zaifu-cho, Hirosaki, Aomori 036-8562, Japan.

E-mail address: a.fukuipon@mac.com (A. Fukui).

<http://dx.doi.org/10.1016/j.gmit.2016.05.001>

2213-3070/Copyright © 2016, The Asia-Pacific Association for Gynecologic Endoscopy and Minimally Invasive Therapy. Published by Elsevier Taiwan LLC. This is an open access article under the CC BY-NC-ND license (<http://creativecommons.org/licenses/by-nc-nd/4.0/>).

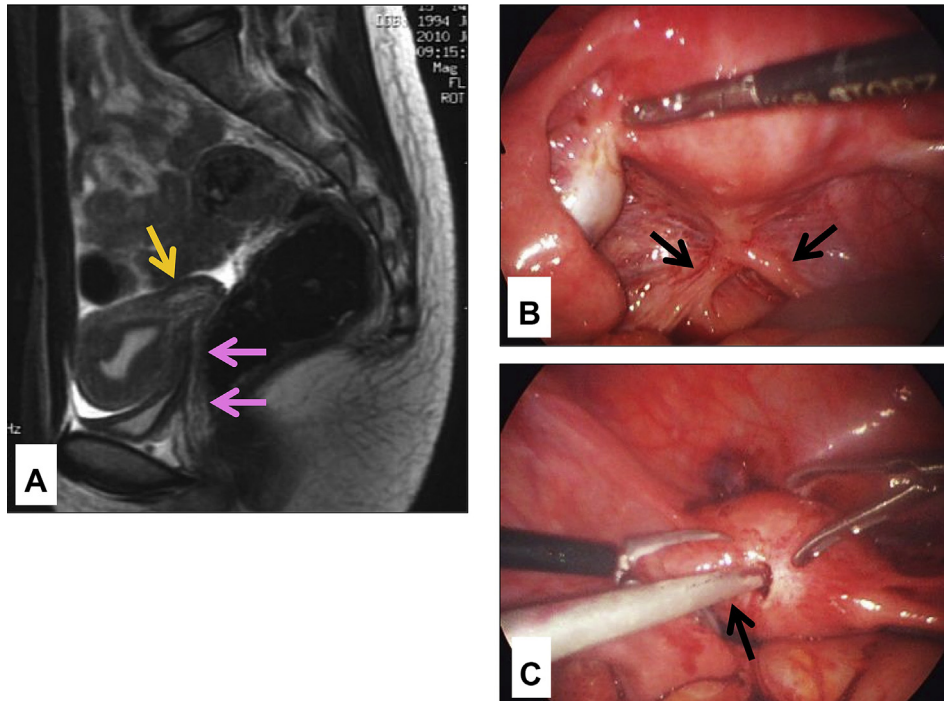


Figure 1. Imaging findings of the genital organs. Magnetic resonance imaging (MRI) findings, sagittal section. (A) The uterine cervix is small (yellow arrow) and the vagina is unobservable (pink arrows). (B) The body of the uterus and bilateral adnexa were normal, but the uterine cervix was thin and short, so bilateral uterosacral ligaments approached toward the midline (black arrows). (C) The uterus was opened at the fundus using a monopolar needle and an Endo Onion was inserted (black arrow) and strongly pushed inferiorly to reveal the uterine cervix.

monopolar needle, and an Endo Onion (Hakko, Tokyo, Japan) was inserted and strongly pushed inferiorly (Figure 1C). This maneuver made it easy to reveal and open the external os. Five 3–0 Vicryl (Ethicon, Johnson and Johnson, Tokyo, Japan) circular sutures were placed in the cervix to form the vaginal portion of the cervix. Hys-cath (Sumitomo Bakelite Co. Ltd., Tokyo, Japan) was inserted to keep the neo-uterine cervix open for 1 month. The uterine fundus was closed using a 2–0 PDS (Ethicon, Johnson and Johnson) suture. The endometriotic lesion was electrocauterized by an argon plasma coagulator. The blood loss was 100 mL and surgical time was 2 hours and 5 minutes (Figure 2).

To avoid a vaginal wall adhesion and to prevent infection, an originally mixed (1:1:1) vaginal cream consisting of an estradiol gel (Divigel 0.1%), antibiotic (gentamicin) cream (Gentacin Cream 0.1%), and lidocaine hydrochloride jelly (Xylocaine 2% jelly) was applied twice daily. The postoperative course was excellent, and the patient left the hospital 10 days after the surgery. She visited our hospital for follow-up examinations after the surgery once every 1 or 2

weeks. Hys-cath was kept in the uterus until menstruation. The menstruation occurred 25 days after the surgery. Dysmenorrhea was clinically relieved, and the patient was free of cervical stenosis. The vaginal wall color gradually turned pink, indicating a regeneration of the vaginal epithelium. Cytodiagnosis of the uterine cervix was performed 26 days after the surgery and revealed few squamous epithelial cells on a background of inflammatory cells. The second menstruation occurred 3 months after the surgery. Three years after the surgery, the patient visits our hospital once every 1 to 2 months. She remains free of cervical stenosis and is able to have normal sexual intercourse.

Discussion

We reported the case of a cervical atresia and vaginal aplasia that were successfully treated laparoscopically. Total hysterectomy was previously the recommended treatment for cases of vaginal aplasia with a functional uterus.^{1,5} Today, there is a tendency to

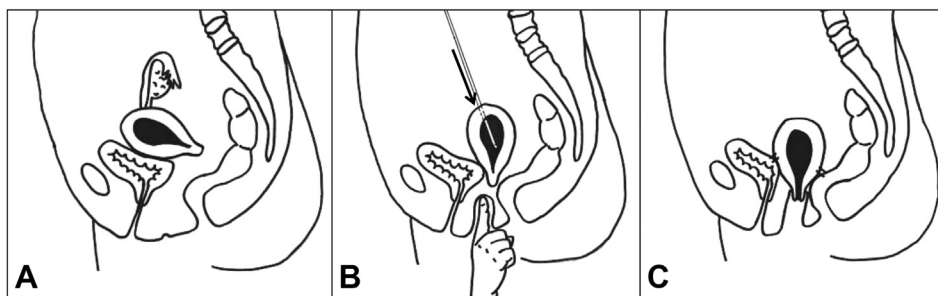


Figure 2. Surgical maneuver schemas. (A) Prior to the operation, the uterine cervix is small and the vagina is unobservable. The neovagina was manually constructed between the bladder and the rectum, and toward the uterus. (B) The Endo Onion was inserted into the uterus and strongly pushed inferiorly to reveal the uterine cervix. (C) The uterus was sutured with the peritoneum.

preserve the uterus. Fedele et al⁴ reported a laparoscopic technique in 2008. We performed a laparoscopically assisted cervical canalization in reference to their report. In this case, we opened the uterine fundus to reveal the uterine cervix clearly. This patient had cervical atresia and vaginal aplasia, so neovagina and neo-uterine cervix had to be created precisely. It is important to create the cervical canal correctly and carefully to avoid causing injury to the urinary bladder, urethra, and rectum, and for sexual intercourse, menstruation, pregnancy, and delivery. However, a more minimal invasive surgery for the uterus may be necessary. As a possible maneuver, without opening the uterine fundus, grip the fundus or bilateral round ligaments of the uterus and push inferiorly. Otherwise, the method of digging to the direction of the uterus under the guidance of ultrasonography from the vaginal side may be possible.⁶ The method of the cervical canal opening for these patients should be discussed more in the future. There are numerous reports of neovaginoplasty techniques such as the Ruge,⁷ Wharton,⁸ McIndoe,⁹ and Davydov¹⁰ methods. The common basic maneuvers of these techniques include separating the bladder and the rectum through the vulva, and constructing inner walls of the neovagina using the sigmoid colon (Ruge), a mold (Wharton), skin (McIndoe), or peritoneum (Davydov). In our case, starting from the external genitalia, we created a space between the bladder and the rectum to form the neovagina, and continued this space until the neovaginal inner wall reached the original squamous epithelium. We did not use a bowel segment, the skin, or peritoneum as a graft to cover the vaginal walls. To prevent adhesion and promote epithelialization, we used an estrogen-containing cream. Moreover, we did not use a mold. Because the body of the uterus was developed in this case, a neovagina was created by applying traction to the body of the uterus.

A specially made cream, a mixture of an estradiol gel, gentamicin cream, and lidocaine hydrochloride jelly, was used in this case; the gel to promote a squamous metaplasia of the vaginal walls, the cream to protect the vaginal walls against bacterial infection, and the jelly to relieve pain.

There are three purposes for using the described surgical procedure: to immediately relieve dysmenorrhea, to allow for sexual intercourse, and to allow for pregnancy and childbirth in the future. According to different reports, menstruation occurred regularly in all patients who underwent cervical canalization; however, in one case there was a need for a reoperation because of secondary cervical atresia. In our case, the patient felt relieved to have a first menstruation and was satisfied by a significant improvement of the dysmenorrhea. Deffarges et al³ reported that 12 of the 18 patients who underwent surgery were able to have sexual intercourse, and Fedele et al⁴ reported this in 6 out of 12 cases. In our case, the patient was able to have normal sexual intercourse without pain, so she was satisfied with her sexual life. There are several reports of patients who achieved natural pregnancy after surgery. Deffarges et al³ reported that 10 out of 18 patients who underwent a surgery to treat uterine cervical atresia desired pregnancy; of this total, four had a pregnancy, and the total number of pregnancies resulting from these four patients was six. All cases were delivered by cesarean section between 36 and 38 weeks of pregnancy. There was a need for a cervical cerclage in one case, and the average birth

weight of the newborns was 2400 g.³ Chakravarty et al² reported that two out of 18 patients achieved pregnancy and gave birth. Jasonni et al¹¹ reported that one out of three patients achieved pregnancy and required bed rest and tocolysis because of cervical shortening and dilation; however, this patient delivered a baby of 2650 g by cesarean section. All cases may not become threatened by abortion or premature birth. There are cases that require bed rest or cervical cerclage; by contrast, there are cases that require no treatment. The accumulation of cases is still necessary to evaluate the prognosis of pregnancy and delivery of the postoperative uterine cervical aplasia. Therefore, a laparoscopically assisted cervical canalization for patients with cervical atresia and vaginal aplasia may be promising not only for relief from dysmenorrhea but also for future natural conception.

Conclusion

We reported the case of a uterine cervical atresia and vaginal aplasia. If treatment is delayed, patients may suffer from pelvic endometriosis, hematosalpinx, and infertility; therefore, timing of surgery is very important. When a young woman presents with primary amenorrhea and cyclical abdominal pain, clinicians should consider Müllerian duct abnormality as a possibility. In this case, we observed a squamous metaplasia of the neovaginal inner wall that was not coated with either a bowel graft or a skin graft. Estrogen-containing cream was applied to the neovagina after the surgery that was performed without using prosthesis. Three years after the operation, the patient is free of vaginal stenosis or cervical atresia, and is also able to have sexual intercourse. Long-term follow-up is necessary in order to ensure a future pregnancy and childbirth.

References

1. Fujimoto VY, Miller JH, Klein NA, Soules MR. Congenital cervical atresia: report of seven cases and review of the literature. *Am J Obstet Gynecol.* 1997;177:1419–1425.
2. Chakravarty B, Konar H, Chowdhury NN. Pregnancies after reconstructive surgery for congenital cervicovaginal atresia. *Am J Obstet Gynecol.* 2000;183:421–423.
3. Deffarges JV, Haddad B, Musset R, Paniel B. Utero-vaginal anastomosis in women with uterine cervix atresia: long-term follow-up and reproductive performance. A study of 18 cases. *Hum Reprod.* 2001;16:1722–1725.
4. Fedele L, Bianchi S, Frontino G, Berlanda N, Montefusco S, Borruto F. Laparoscopically assisted uterovestibular anastomosis in patients with uterine cervix atresia and vaginal aplasia. *Fertil Steril.* 2008;89:212–216.
5. Rock JA, Schlaff WD, Zacur HA, Jones Jr HW. The clinical management of congenital absence of the uterine cervix. *Int J Gynaecol Obstet.* 1984;22:231–235.
6. Seet MJ, Lau MSK, Chan JKY, Tan HH. Management of complete vagino-uterine septum in patients seeking fertility: report of two cases and review of literature. *Gynecol Minim Invas Ther.* 2015;4:140–145.
7. Ruge E. Ersatz der vagina durch die flexur mittels Laparotomie. *Deut Med Wschr.* 1914;40:120–122.
8. Wharton K. A simplified method of constructing a vagina. *Ann Surg.* 1938;107:842–847.
9. McIndoe A. An operation for the cure of congenital absence of the vagina. *J Obstet Gynaecol.* 1938;45:490.
10. Davydov S. Colpopoiesis from the peritoneum of the utero-rectal space. *Obstet Gynecol.* 1969;12:55–57.
11. Jasonni VM, La Marca A, Matonti G. Utero-vaginal anastomosis in the treatment of cervical atresia. *Acta Obstet Gynecol Scand.* 2007;86:1517–1518.